

Laparoscopic Wedge Resection of Gastric Leiomyoma

Atul K. Madan, MD, Constantine T. Frantzides, MD, PhD, Ali Keshavarzian, MD, Claire Smith, MD

ABSTRACT

Gastric leiomyoma is a relatively rare gastric neoplasm. Before the routine use of laparoscopy, various methods of treatment for gastric leiomyoma included open celiotomy with gastric wedge resection, partial gastrectomy, enucleation, and extended gastrectomy with en bloc resection of adjacent organs. Below, we describe a case of laparoscopic wedge resection and review the various laparoscopic techniques for the treatment of gastric leiomyoma.

Key Words: Laparoscopy, Gastric leiomyoma.

INTRODUCTION

Gastric leiomyomas represent 2.5% of gastric neoplasms.^{1,2} Although most are asymptomatic, they may enlarge or result in upper gastrointestinal hemorrhage. Most symptomatic patients present with postprandial fullness and gastrointestinal hemorrhage; however, other patients present with an incidental submucosal filling defect on upper gastrointestinal contrast studies or a smooth effacement of gastric mucosa overlying a submucosal mass (Schindler's sign³) on endoscopy. Although leiomyoma is classically a submucosal lesion, intraluminal or extramural growth has been noted.

Open celiotomy with gastric wedge resection, partial gastrectomy, enucleation, and extended gastrectomy with en bloc resection of adjacent organs are various methods of treatment for gastric leiomyoma before the use of laparoscopy. With the progression of laparoscopic surgery beyond laparoscopic cholecystectomy, laparoscopic wedge resection has become the ideal treatment for gastric leiomyomas. Below, we describe a case of laparoscopic wedge resection and review the various laparoscopic techniques used to treat gastric leiomyoma.

CASE REPORT

A 60-year-old female presented to the emergency room with complaints of hematemesis. An upper endoscopy demonstrated a 2-cm lesion on the greater curvature of the stomach 6 cm from the gastroesophageal junction. Small ulcerations of this mass were noted but no active bleeding. The patient remained hemodynamically stable without any changes in her hematocrit. A contrast upper gastrointestinal series displayed a well-circumscribed mass in the region of the upper gastric body (**Figure 1**).

Laparoscopic treatment of the neoplasm was offered. Intraoperatively, a small, white, smooth, well-encapsulated nodule was noted on the greater curvature lying among the short gastric vessels. The short gastric vessels were divided by using the Harmonic scalpel (UltraCision Ethicon Endo-Surgery, Cincinnati, Ohio) to completely free and visualize the mass (**Figure 2**). Intraoperative endoscopy was utilized for confirmation as well. A wedge resection of the mass with a rim of normal gastric

Department of Surgery, University of Tennessee–Memphis, USA (Dr Madan).

Department of Surgery, Rush University, Chicago, Illinois, USA (Dr Frantzides).

Section of Gastroenterology and Nutrition, Department of Medicine, Rush University, Chicago, Illinois, USA (Dr Keshavarzian).

Department of Diagnostic Radiology and Nuclear Medicine, Rush University, Chicago, Illinois, USA (Dr Smith).

Address reprint requests to: Constantine T. Frantzides, MD, PhD, FACS, Professor of Surgery, Director of Minimally Invasive Surgery Program, Rush University, 1725 W Harrison St, Ste 818, Chicago, IL 60612, USA. Telephone: 312 942 6511, Fax: 312 942 6520, E-mail: Constantine_T_Frantzides@rush.edu

© 2004 by JSLS, Journal of the Society of Laparoendoscopic Surgeons. Published by the Society of Laparoendoscopic Surgeons, Inc.

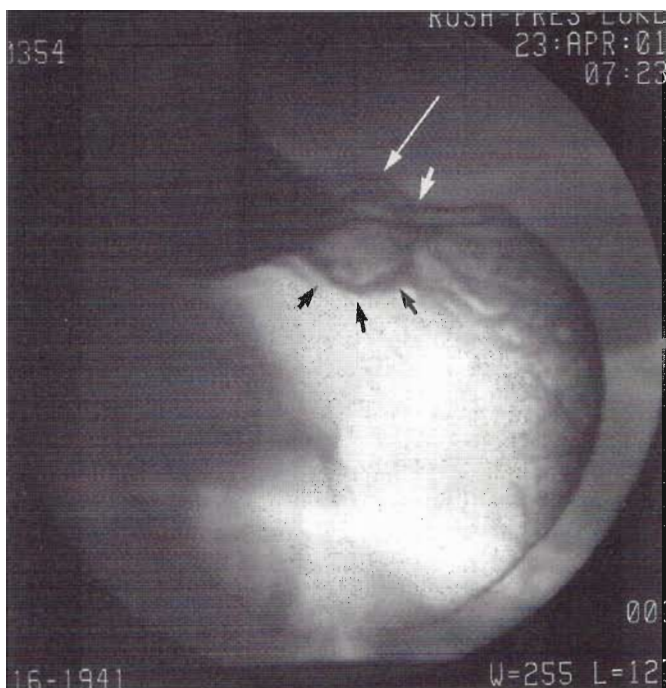


Figure 1. Digital spot film from an upper gastrointestinal examination demonstrating the gastric mass located in the proximal stomach. Small arrows outline a smooth mucosal surface. The short white arrows point to the classic “right angle deformity” indicating a submucosal location by radiographic criteria. The long white arrows show the bulging contour deformity on the external surface of the stomach.

tissue was performed with a laparoscopic stapling device (**Figure 3**). Pathology revealed a gastric leiomyoma with negative margins.

Postoperatively, the patient did well, was discharged the next day with oral pain medications, and was seen in the clinic in follow-up without any problems.

DISCUSSION

The first gastric stromal tumor was noted at autopsy in 1762,⁴ however, the first successful resection was performed over 100 years later. Gastric stromal tumors are divided into 3 groups based on malignant potential: leiomyoma, leiomyosarcoma, and leiomyoblastomas. The first case of laparoscopic gastric leiomyoma resection was reported in 1992.⁵ This leiomyoma was found incidentally during a laparoscopic cholecystectomy. Since then, various laparoscopic approaches to leiomyoma have

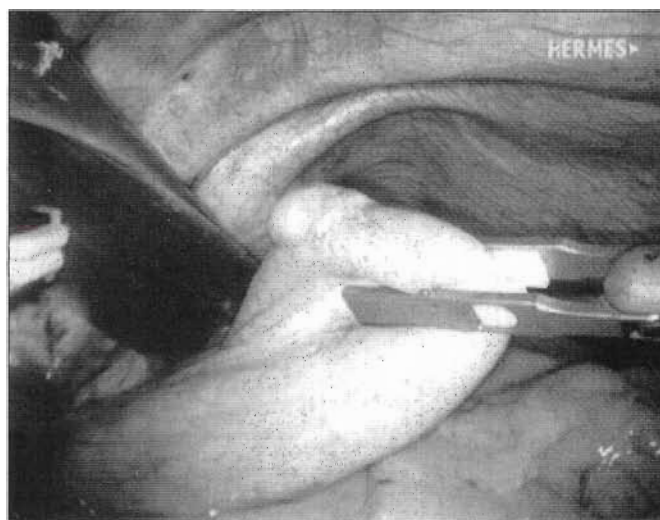


Figure 2. Laparoscopic demonstration of the gastric leiomyoma.

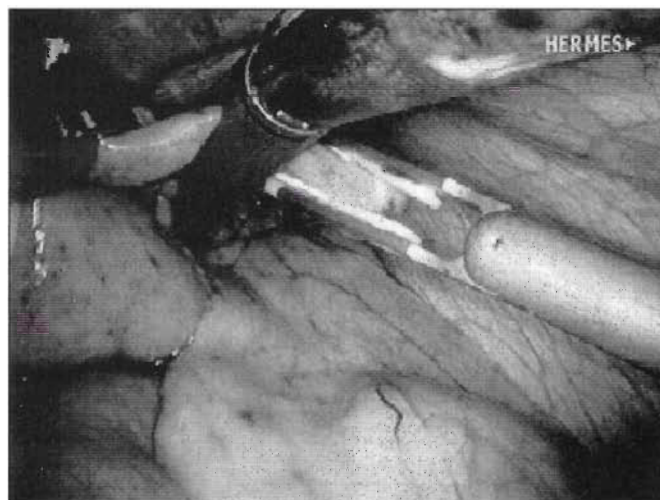


Figure 3. An endoscopic stapler was used to resect the gastric leiomyoma.

been discussed. These methods have been applied to other benign gastric tumors (eg, submucosal gastric lipoma⁶) as well as leiomyosarcoma.⁷ Gastric resection without lymph node dissection in the treatment of malignant neoplasm (such as leiomyosarcoma) may be controversial although studies have demonstrated no benefit from the addition of systemic lymph node dissection or more

extensive resection in the treatment of leiomyosarcoma.^{8,9} These results are important when considering the laparoscopic technique for any gastric stromal tumor resection because often the diagnosis of leiomyosarcoma versus leiomyoma may not be evident until after resection. In fact, biopsies from endoscopy yield the diagnosis in less than 60% of the time.^{10,11} Although some authors feel that more extensive resections may be necessary for high-grade leiomyosarcoma,¹² others believe that a wedge resection is sufficient for leiomyosarcomas.^{8,9}

Four major laparoscopic methods have been described for the resection of gastric leiomyoma. The choice of technique should be based both on size and location of the lesion. For easily accessible anterior lesions, a simple wedge resection¹²⁻¹⁴ is possible via an endostapling device although some have suggested the use of laparoscopic suturing as a more cost-effective method.¹⁵ We, like others, prefer the use of an endostapling device to reduce operative time as well as to avoid contamination from a gastrotomy.¹⁶ Simple wedge resection has also been described for the use of posterior lesions via access through the lesser sac.¹⁵ Because the lesion in our patient was on the greater curvature and easily accessible after dissection of the short gastric vessels, a wedge resection was the method we chose to use.

Lesions on the posterior wall, close to the gastroesophageal junction, or close to the pylorus may be difficult or impractical for a simple wedge resection. Also, resection of a tumor close to the gastroesophageal junction or the pylorus may cause significant postoperative stenosis. Thus, laparoscopic resection via an anterior gastrotomy has been described.^{15,17-20} With this technique, an anterior gastrotomy is first performed; then, the mass is removed either with all layers of the posterior gastric wall or removed leaving the posterior gastric wall partially intact. Closure of the defect can be performed via the anterior gastrotomy via laparoscopic stapling or suturing techniques.

Another method described is the combined use of laparoscopic, endoscopic, and intragastric techniques for the resection.²¹⁻²³ This technique is ideal for lesions that are difficult to excise with a simple wedge resection. Utilizing this method, the abdomen is first entered and insufflated. Then, an endoscope is placed in the stomach that is also insufflated. An alternative method is to directly enter the stomach without intraabdominal insuffla-

tion.²³ Either laparoscopic or minilaparoscopic ports are placed intragastrically. The minilaparoscopic or needleoscopic (2-mm) ports do not usually require closure, which offers a specific advantage over standard laparoscopic ports.^{22,23} Resection of the leiomyoma leaving the serosa intact is performed with visualization via the endoscope. Some authors close the intragastric defect with intragastric suturing,²³ while others leave the defect open.²² The specimen can be removed transorally via endoscopy.

The final method is enucleation of gastric leiomyomas.²⁴ The seromuscular layers are dissected from the gastric mucosa to allow for enucleation of the leiomyoma. The utilization of this technique has significant drawbacks. Because preoperatively, the distinction between leiomyoma and leiomyosarcoma is not always known, rupture of the tumor mass or incomplete resection would be inappropriate treatment. Thus, simple enucleation is not recommended for these lesions.^{25,26}

No matter which technique is used, intraoperative endoscopy is a useful adjunct especially when trying to localize small tumors. Frozen section should always be considered in order to (1) exclude other possible diagnoses and (2) to assure clear margins. Differentiating from high-grade and low-grade lesions by frozen section is not accurate however.

Laparoscopic surgery for gastric leiomyoma offers the usual advantages of the minimally invasive approach. Postoperative recovery is short as demonstrated by our case with a 1-day postoperative hospital stay. This shorter stay should translate into a reduction in pulmonary and infectious complications related to extended hospital stays. Another advantage is smaller incisions (better cosmesis) and thus subsequent decreased postoperative pain and narcotic requirement. Laparoscopic surgery for gastric leiomyoma offers a safe and effective approach compared with open laparotomy.

References:

1. Marshall SF. Symposium of surgery of digestive tract. Gastric tumors other than carcinoma. *Surg Clin North Am.* 1975;35:693-697.
2. Morgan BK, Compton C, Talbert M, Gallagher WJ, Wood WC. Benign smooth muscle tumors of the gastrointestinal tract. A 24 year experience. *Ann Surg.* 1990;211:63-66.
3. Schindler R, Blomquist OA, Thompson HL, Pettler AM. Leiomyosarcoma of the stomach: its roentgenologic and gastro-

- scopic diagnosis and its possible relationship to pernicious anemia. *Surg Gynecol Obstet.* 1946;82:239-252.
4. Morgagni JB. The seats and causes of disease investigated by anatomy. Alexander B, trans. Letter XIX, Article 58. London: AM Cadell Johnson and Payne; 1769:545-549. Reprinted in facsimile edition by the Classics of Medicine Library, Gryphon Editions, Ltd, Birmingham, Alabama; 1983.
5. Lukaszczuk J, Preletz R. Laparoscopic resection of benign stromal tumor of the stomach. *J Laparoendosc Surg.* 1992;2:331-334.
6. Fowler DL, White SA. Laparoscopic resection of a submucosal gastric lipoma: A case report. *J Laparoendosc Surg.* 1991;1:303-306.
7. Otani Y, Ohgami M, Igarashi N, et al. Laparoscopic wedge resection of gastric submucosal tumors. *Surg Laparosc Endosc Percutan Tech.* 2000;10:19-23.
8. Yoshida M, Otani Y, Ohgami M, et al. Surgical management of gastric leiomyosarcoma: Evaluation of the propriety of laparoscopic wedge resection. *World J Surg.* 1997;21:440-443.
9. Ng EH, Pollock RE, Munsell MF, Atkinson EN, Romsdahl MM. Prognostic factors influencing survival in gastrointestinal leiomyosarcomas. *Ann Surg.* 1992;215:68-77.
10. Sanders L, Silverman M, Rossi R, Braasch J, Munson L. Gastric smooth muscle tumors: diagnostic dilemmas and factors affecting outcome. *World J Surg.* 1996;20:992-995.
11. Tatsuta M, Iishi H, Okuda S, Oshima A, Taniguchi H. Prospective evaluation of diagnostic accuracy of gastrofiberscopic biopsy in diagnosis of gastric cancer. *Cancer.* 1989;63:1415-1420.
12. Dempsey DT, Kelberman IA, Dabiezies MA. Laparoscopic resection of gastric leiomyosarcoma. *J Laparoendosc Adv Surg.* 1997;7:357-362.
13. Llorente J. Laparoscopic gastric resection for gastric leiomyoma. *Surg Endosc.* 1994;8:887-889.
14. Payne WG, Murphy CG, Grossbard IJ. Combined laparoscopic and endoscopic approach to resection of excision of gastric leiomyoma. *J Laparoendosc Surg.* 1995;5:119-122.
15. Basso N, Rosata P, DeLeo A, et al. Laparoscopic treatment of gastric stromal tumors. *Surg Endosc.* 2000;14:524-526.
16. Pereira SG, Davies RJ, Ballantyne GH, Duperier T. Laparoscopic wedge resection of a gastric leiomyoma. *Surg Endosc.* 2001;15:896-897.
17. Ibrahim M, Silvestri F, Zingler B. Laparoscopic resection of posterior gastric leiomyoma. *Surg Endosc.* 1997;11:277-279.
18. Piskun G, Fleites JC, Shaftan GW, Fogler RJ. A laparoscopic approach to posterior gastric wall leiomyomectomy. *J Laparoendosc Adv Surg Tech.* 1998;8:75-78.
19. Watson DI, Game PA, Devitt PG. Laparoscopic resection of benign tumors of the posterior gastric wall. *Surg Endosc.* 1996;10:540-541.
20. Seelig MH, Hinder RH, Floch NR, et al. Endo-organ and laparoscopic management of gastric leiomyomas. *Surg Laparosc Endosc.* 1999;9:78-81.
21. Taniguchi H, Kamiike W, Yamanishi H, et al. Laparoscopic intragastric surgery for gastric leiomyoma. *Surg Endosc.* 1997;7:257-263.
22. Tagaya N, Kita J, Logure H, Kubota K. Laparoscopic intragastric resection of gastric leiomyoma using needlescopic instruments [abstract]. *Surg Endosc.* 2001;15:414.
23. Heniford BT, Arca MJ, Walsh RM. The mini-laparoscopic intragastric resection of a gastroesophageal stromal tumor: A novel approach. *Surg Laparosc Endosc Percutan Tech.* 2000;10:82-85.
24. Yamashita Y, Bekki F, Kakegawa T, Umetani H, Yatsuka K. Two laparoscopic techniques for resection of leiomyoma in the stomach. *Surg Laparosc Endosc.* 1995;5:38-42.
25. Appelman HD, Helwig EB. Gastric epithelioid leiomyoma and leiomyosarcoma (leiomyoblastoma). *Cancer.* 1976;38:708-728.
26. Shiu MH, Farr GH, Papachristou DN, Hajdu S. Myosarcomas of the stomach. *Cancer.* 1982;49:177-187.