

RADIONUCLIDE EVALUATION OF THE REVERSIBILITY OF OCCLUSIVE AND NONOCCLUSIVE INTESTINAL ISCHEMIA

Constantine T. Frantzides, MD, PhD,
Anastasia Stavrika, MD, Petros Mirianthepts, MD,
Costas Kakavakis, MD, and
Robert E. Condon, MD, MS, FACS

WE HAVE recently shown that ischemic intestine can be visualized by a noninvasive radionuclide method (1). The aim of the present study was to evaluate the ability of this method to show image changes that could be correlated with reversal of intestinal ischemia.

MATERIALS AND METHODS

Occlusive small intestinal ischemia was induced in 16 dogs by the application of atraumatic microclamps on a main branch of the superior mesenteric artery. Eight mCi of ^{99m}Tc -methylene diphosphonate (TMDP) was injected through a peripheral vein 10 minutes, three hours, or five hours ($n = 6, 5, 5$ for each time point) after closure of the abdominal wall. Abdominal images were taken with a gamma camera one and two hours after the injection of the radionuclide. The animals were reoperated on after varying intervals of ischemia and the mesenteric circulation was

From the Department of Surgery and the Vince Lombardi Cancer Clinic, Medical College of Wisconsin, and the Department of Radiology, University of Athens, Greece.

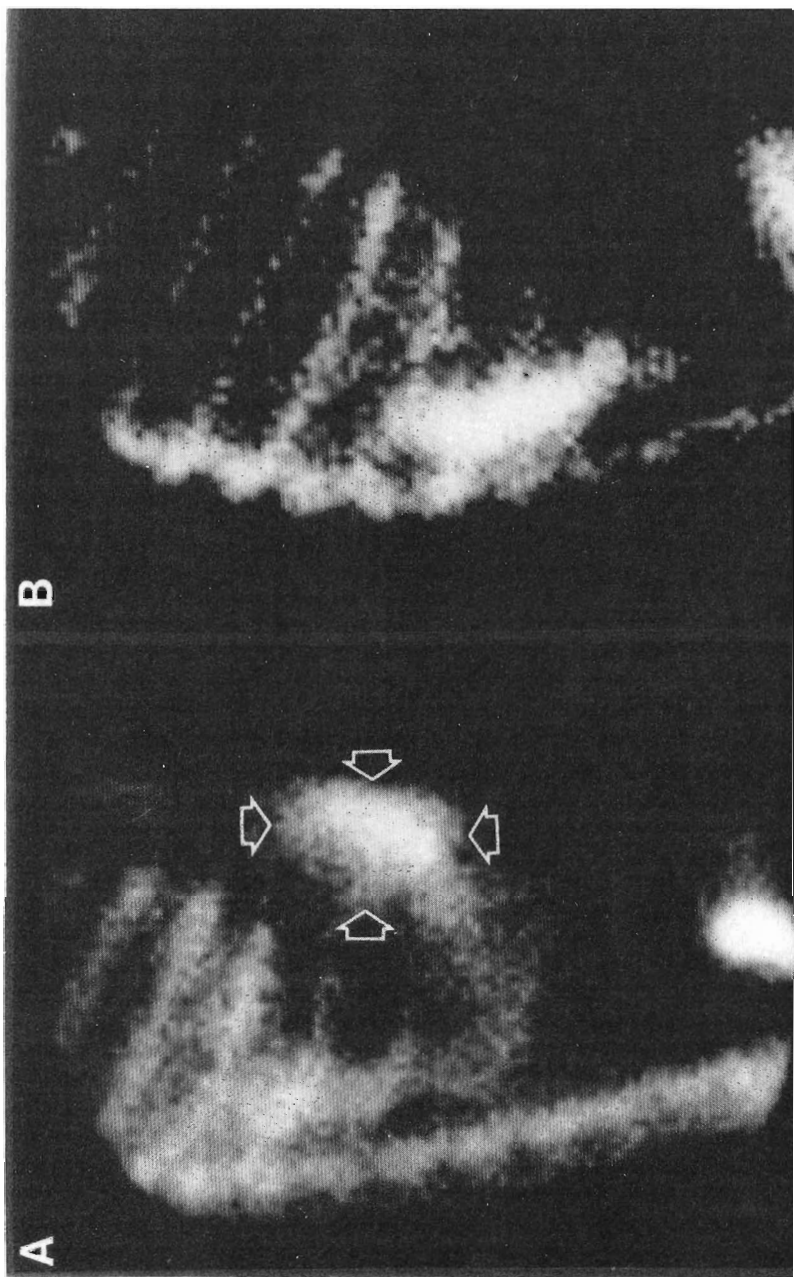


Fig 1—A, in vivo scintigraphic image demonstrating intestinal uptake of radionuclide by intestinal segment subjected to nonocclusive ischemia (arrows). B, image of same animal made 30 minutes after commencement of papaverine infusion. Note disappearance of radioactivity from the ischemic segment.

Table 1—Bowel viability

<i>n</i>	Duration of ischemia	Bowel viable by:		Survivors without gangrene
		Visual criteria	TMDP scan	
6	2 h	6	6	6
5	5 h	4	5	5
5	7 h	3	4	4

reestablished. Viability (pulsation, color, motility) of ischemic intestine was evaluated visually, the abdomen was closed, and serial gamma camera images were taken.

Nonocclusive intestinal ischemia was simulated in four additional dogs by infusion of levarterenol (4 $\mu\text{g}/\text{min}$) via a silicon T-tube into a jejunal mesenteric artery branch. After one hour of levarterenol infusion, TMDP (8 mCi) was injected as a bolus through a peripheral vein and images were obtained for up to two hours. Papaverine (1 mg/min) was then infused through the T-tube and serial gamma camera images were obtained for up to one hour.

RESULTS

All animals subjected to occlusive and nonocclusive intestinal ischemia showed selective uptake of TMDP by the ischemic intestine (Fig 1A). After reestablishment of circulation, radioactivity disappeared within one hour from the ischemic segment in 15 of 16 animals in the occlusive group. In one animal radioactivity persisted for more than three hours and the animal died in two days because of intestinal gangrene and perforation (Table 1). In the nonocclusive group, radioactivity disappeared from the ischemic intestinal segment in all animals within 30 minutes after commencement of papaverine infusion (Fig 1B).

DISCUSSION

Several radionuclide techniques have been evaluated in the past (2-5) to predict the viability of ischemic intestine. These techniques, however, are either invasive or fail to detect early ischemic intestinal lesions. The present study demonstrates that disappearance of radioactivity from the ischemic segment within one hour after reestablishment of circulation indicates intestinal survival, whereas persistence beyond one hour indicates irreversible acute ischemic damage. Radionuclide imaging with TMDP is a sensitive means of predicting the viability of ischemic intestinal segments. This noninterventional method may strengthen the clinical criteria and facilitate decision-making for operative intervention, and may obviate the need for "second look" operations in the management of intestinal ischemia.

REFERENCES

1. Frantzides CT, Condon RE, Tsiftsis D, et al: Radionuclide visualization of acute occlusive and non-occlusive intestinal ischemia. *Ann Surg* 203:295-300, 1986
 2. Moossa AR, Skinner DB, Sark V, et al: Assessment of bowel viability using ^{99m}Tc -tagged albumin microspheres. *J Surg Res* 16:466-472, 1974
 3. Zarins CK, Skinner DB, Rhodes BA, et al: Prediction of the viability of revascularized intestine with radioactive microspheres. *Surg Gynecol Obstet* 138:576-580, 1974
 4. Schimmel DH, Moss AA, Huffer PB: Radionuclide imaging of intestinal infarction in dogs. *Invest Radiol* 11:277-281, 1976
 5. Kressel NY, Moss AA, Montgomery CK, et al: Radionuclide imaging of bowel infarction complicating small bowel intussusception in dogs. *Invest Radiol* 13:127-131, 1978
-