

Radionuclide Visualization of Acute Occlusive and Nonocclusive Intestinal Ischemia

CONSTANTINE T. FRANTZIDES, M.D.
ROBERT E. CONDON, M.D., M.S., F.A.C.S.

DEMITRIOS TSIFTSIS, M.D.
A. STAVRAKA, M.D.

CHRISTOS PISSIOTIS, M.D., F.A.C.S.
JOHN PAPADEMETRIOU, M.D., F.A.C.S.

A noninvasive radionuclide technique to visualize ischemic small intestine was evaluated. Vascular ligation of 20–30 cm ileum was done in rabbits. After induction of ischemia, technetium (^{99m}Tc) methylene diphosphonate (TMDP) was injected IV at intervals up to 24 hours. Images were recorded 1 and 3 hours after injection of radioisotope and showed preferential (9:1) uptake by ischemic bowel. Positive scans were present in all animals up to 4 hours and in 75% at 10–12 hours, but in none 24 hours after induction of ischemia. Nonocclusive intestinal ischemia was simulated in 4 dogs by infusing norepinephrine into a jejunal mesenteric arterial branch. After 1 hour, an IV bolus of TMDP was injected and images recorded at intervals up to 3 hours. Selective uptake of isotope by the ischemic segment was observed in all animals. Angiography confirmed that isotope uptake was confined to the infused segment. These studies show that occlusive intestinal ischemia can be detected, by radionuclide imaging up to 12 hours, and nonocclusive (low flow) ischemia for at least 4 hours, after onset.

ACUTE INTESTINAL ISCHEMIA requires urgent diagnosis and treatment to prevent ultimate intestinal infarction and necrosis. Clinical evaluation in the early stages of intestinal ischemia may be misleading. Even when the diagnosis is entertained early, conventional diagnostic confirmation using invasive imaging techniques, such as angiography, may be deferred. Radionuclide techniques permitting diagnosis and localization of acutely ischemic or infarcted myocardium have been developed recently.^{2,7,8,10,12} This study adapts similar noninvasive scintigraphic techniques to the problem of diagnosis of acute intestinal ischemia.

We evaluated a noninvasive radionuclide technique for the visualization of acute occlusive and nonocclusive intestinal ischemia. Our objectives were: (1) to determine whether various types of mesenteric ischemic lesions could

From the Department of Surgery, The Medical College of Wisconsin, Milwaukee, Wisconsin, and the Second Surgical Clinic, University of Athens, Athens, Greece

be detected after administration of technetium methylene diphosphonate (TMDP), (2) to determine the degree and duration of ischemic injury needed to create the minimal lesion detectable by this method, and (3) to evaluate the ability of TMDP to visualize nonocclusive intestinal ischemia.

Methods

Experiments were conducted in 65 albino New Zealand rabbits weighing 3 to 5 kg. The experiments conformed with all institutional guidelines and met AALAC standards. A midline laparotomy was performed under general anesthesia induced with thiopental sodium, 20 mg/kg IV. Five sham-operated animals served as nonischemic controls. In three groups of 20 rabbits each, ischemia was induced in a 20–30 cm segment of terminal ileum by isolated mesenteric venous occlusion, isolated mesenteric arterial occlusion, or by intestinal strangulation (Fig. 1). The arterial or venous occlusions were accomplished by ligating a main branch of the superior mesenteric artery or vein together with ligation of all anastomotic arterial or venous branches on the border of the intestinal segment under study. Intestinal strangulation was induced by mass ligation of a 20 cm loop of intestine including its mesentery. Occlusion of the mesenteric vessels included in the strangulated loop was only partial.

Subsets of five animals in each group received an intravenous bolus of 2 mCi ^{99m}Tc methylene diphosphonate (TMDP) via a peripheral vein 10 minutes, 1 hour, 9 hours, and 21 hours following induction of ischemia. Abdominal images were taken with a gamma camera (OPT-Camera,

Reprint requests: Robert E. Condon, M.D., Department of Surgery, 8700 West Wisconsin Avenue, Milwaukee, WI 53226.

Submitted for publication: October 19, 1985.

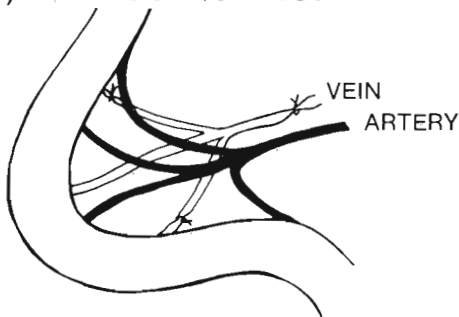
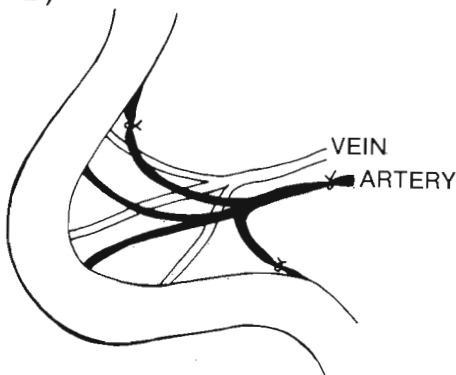
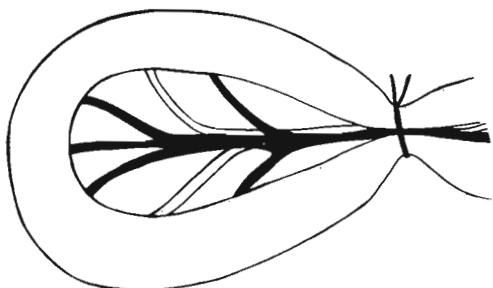
A) VENOUS LIGATION**B) ARTERIAL LIGATION****C) INTESTINAL STRANGULATION**

FIG. 1. Diagrammatic representation of the three types of occlusive intestinal ischemia studied.

Companie General de Radiologie, Paris, France) with a high resolution parallel hole collimeter in the anterior and left lateral projections at 1 and 3 hours after the administration of the radionuclide bolus. After completion of the experiment, animals were sacrificed by IV injection of thiopental sodium (40 mg/kg) and segments from ischemic and adjacent nonischemic intestine were examined by light microscopy. Ischemic and nonischemic comparison segments of bowel were also studied by *in vitro* scintigraphic imaging. Tissue samples from ischemic and

normal bowel were assayed for radioactivity (cpm/gram wet tissue weight) using a gamma scintillation counter.

Nonocclusive intestinal ischemia was induced in four conditioned dogs weighing 25–35 kg. A midline laparotomy was performed under general anesthesia induced with pentobarbital, 25 mg/kg. A jejunal branch of the superior mesenteric artery, 50 cm distal to the ligament of Trietz, was isolated from adjacent tissues, clamped proximally and distally with microclamps, and incised transversely. A t-shaped silastic tube was inserted into the artery and sutured to the vessel and the adjacent mesentery (Fig. 2). The microclamps were then released and circulation re-established.

The length of intestine perfused primarily by the cannulated artery varied from 15–20 cm and was confirmed by angiography. The long limb of the catheter was tunneled subcutaneously to the subscapular region and protected by a jacket. The abdomen was closed and the animals permitted to recover for 7 days. The catheter was kept patent by flushing with heparinized saline (1000 units/ml) three times daily.

After the week of recovery, general anesthesia was again induced and 4 mCi TMDP injected intravenously. Abdominal scintigrams were obtained by a gamma camera (Picker Dyna-Camera) 30, 60, 90, and 180 minutes after radionuclide injection. These images were used as controls. Two days later, nonocclusive intestinal ischemia was simulated by infusion of norepinephrine, 4 μ g/min, *via* the catheter for 4 hours. One hour after beginning the norepinephrine infusion, 4 mCi TMDP was injected intravenously and external abdominal scans were again obtained after 30, 60, 90, and 180 minutes.

Results

Regardless of the type of occlusive intestinal injury (arterial, venous, strangulation), ischemic intestinal segments were visualized in all animals by external scans taken 1–

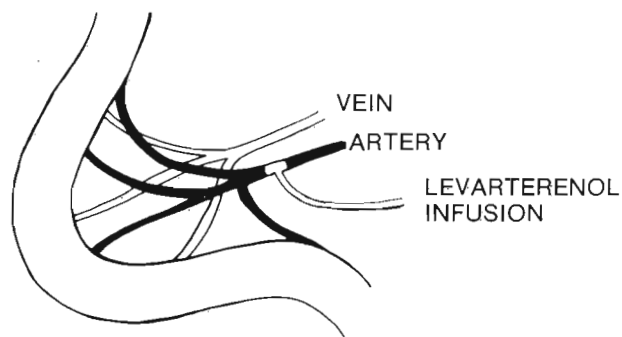
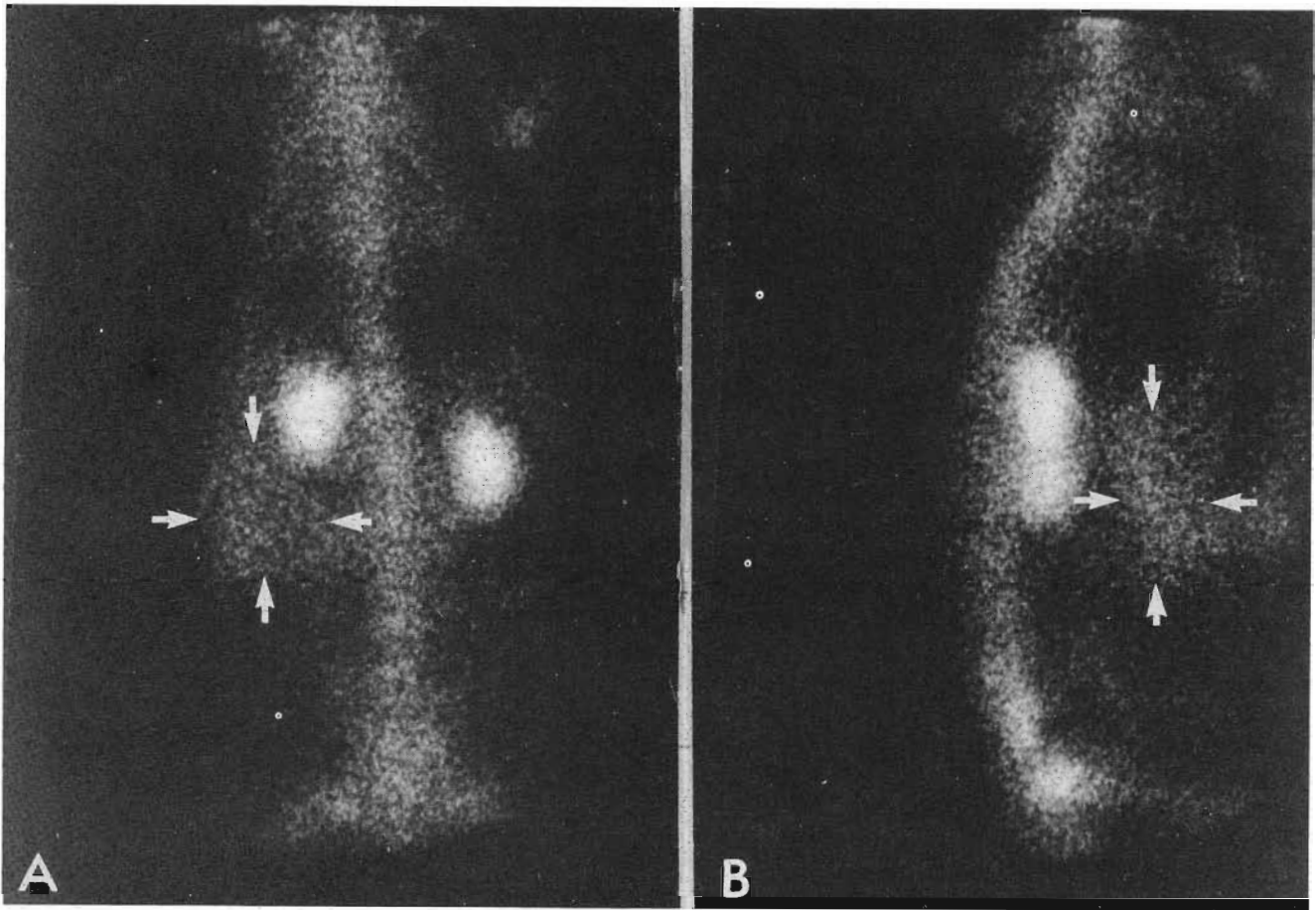


FIG. 2. Nonocclusive intestinal ischemia induced by local intra-arterial infusion of norepinephrine *via* a t-shaped catheter into an unobstructed mesenteric artery.



FIGS. 3A and B. *In vivo* scintigraphic image obtained 4 hours following arterial occlusion. The anterior (A) and lateral (B) views of the abdomen show increased radionuclide uptake (arrows), representing ischemic small bowel, located just caudad to the right kidney.

4 hours after induction of ischemia (Fig. 3; Table 1). Positive scans were present in three-fourths of animals 10–12 hours after induction of ischemia. No positive scans were observed in surviving animals subjected to 21–24 hours of ischemia. Sham-operated controls in which ischemia was not induced showed no uptake of TMDP by intestine, although uptake was noted in the skeletal and urinary systems.

Tissue samples assayed for radioactivity confirmed increased radionuclide uptake in ischemic intestine. The mean ischemic:normal tissue uptake ratio was 9:1 (Fig. 4). Histologic examination of the test segments in animals having induced occlusive ischemia showed evidence of intestinal ischemia or infarction in 59/60 preparations. One animal failed to demonstrate histologic evidence of ischemia and also had a negative TMDP scan.

All animals subjected to simulated nonocclusive mesenteric ischemia visualized the ischemic loop of intestine on TMDP scanning. All scintigrams obtained of these

nonocclusive ischemic segments demonstrated an area of increased radionuclide uptake corresponding to the area of the ischemic-perfused bowel (Fig. 5). All control abdominal scintigrams were normal, *i.e.*, radionuclide uptake only occurred in the skeletal and urinary systems and there was no uptake in the bowel (Fig. 6).

Discussion

In animals subjected to occlusive intestinal ischemia, positive TMDP scans were obtained up to 12 hours after onset of ischemia. The concentration of radionuclide was considerably higher in these ischemic loops compared to normal bowel in the same animal. Of particular importance is the observation that radionuclide imaging of an ischemic bowel loop can be achieved as early as 1 hour following onset. The mechanism by which TMDP accumulates selectively in ischemic intestinal lesions is not clear. The hypothesis of Zimmer and colleagues¹⁴ that

TABLE 1. Summary of Results Obtained in Several Models of Intestinal Ischemia

| Group | Number of Animals Operated on | Time of ^{99m} Tc-MDP Injection | Time of Scan | Number of Animals Surviving | Positive Scan | Histologic Changes |
|-------------------------------------|-------------------------------|---|--------------|-----------------------------|---------------|--------------------|
| Group I (Control) | 5 | 10 minutes | 1-3 hours | 5 | 0/5 | 0/5 |
| Group II (Venous Occlusion) | 5 | | | | | |
| Subgroup A | 5 | 10 minutes | 1-3 hours | 5 | 5/5 | 5/5 |
| Subgroup B | 5 | 1 hour | 2-4 hours | 5 | 5/5 | 5/5 |
| Subgroup C | 5 | 9 hours | 10-12 hours | 5 | 3/5 | 5/5 |
| Subgroup D | 5 | 21 hours | 22-24 hours | 3 | 0/3 | 5/5 |
| Group III (Arterial Occlusion) | | | | | | |
| Subgroup A | 5 | 10 minutes | 1-3 hours | 5 | 5/5 | 5/5 |
| Subgroup B | 5 | 1 hour | 2-4 hours | 5 | 5/5 | 5/5 |
| Subgroup C | 5 | 9 hours | 10-12 hours | 5 | 4/5 | 4*/5 |
| Subgroup D | 5 | 21 hours | 22-24 hours | 2 | 0/2 | 5/5 |
| Group IV (Intestinal Strangulation) | | | | | | |
| Subgroup A | 5 | 10 minutes | 1-3 hours | 5 | 5/5 | 5/5 |
| Subgroup B | 5 | 1 hour | 2-4 hours | 5 | 5/5 | 5/5 |
| Subgroup C | 5 | 9 hours | 10-12 hours | 4 | 3/4 | 5/5 |
| Subgroup D | 5 | 21 hours | 22-24 hours | 1 | 0/1 | 5/5 |

* In Subgroup C of Group III, one animal exhibited negative abdominal scintigraphy and no histologic evidence of ischemic injury.

enzymes released by ischemic tissues may act as receptors to bind TMDP may explain our observations. But the pathway by which the radionuclide reached the devascularized segment of intestine remains an enigma. Residual intramural circulation has been postulated as a possible route.¹

Moossa and coworkers⁵ used radio-labelled albumin microspheres to assess bowel viability after mesenteric vascular occlusion in dogs and monkeys. Their technique required infusion of the labelled microspheres into the abdominal aorta near the origin of the superior mesenteric artery. Furthermore, ischemic intestine was visualized

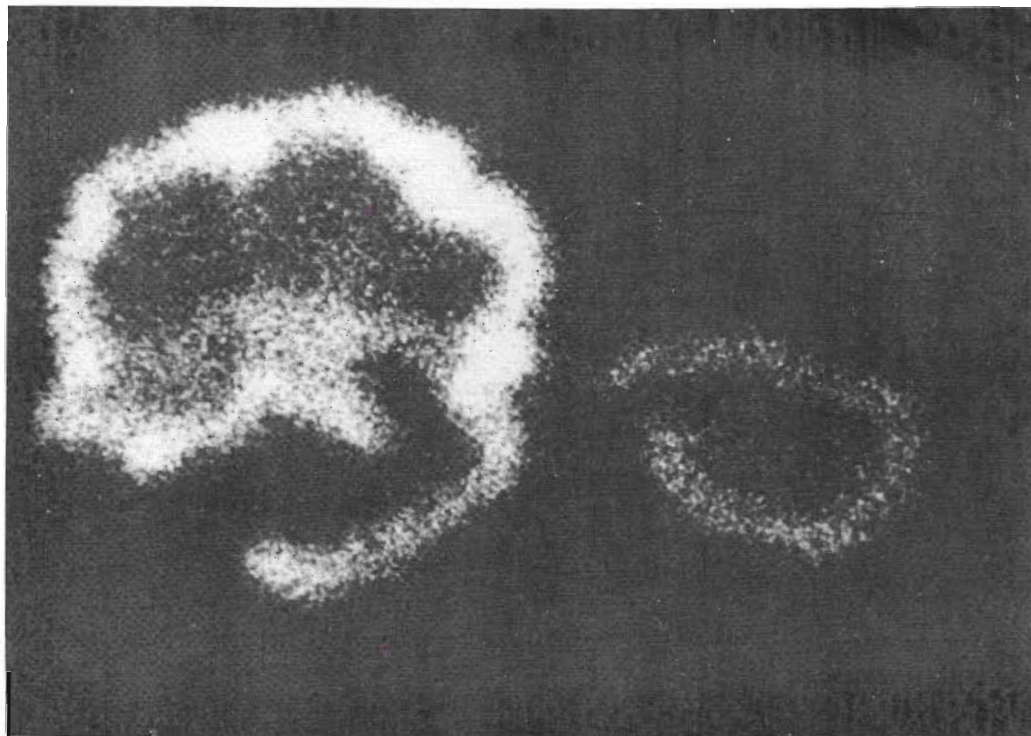


FIG. 4. Scintigraphic image of excised ischemic small bowel (left) and normal small bowel (right) showing preferential uptake of radionuclide by ischemic bowel. The ischemic:normal ratio of activity/g of tissue was 9:1.

only when the bowel was externalized. Zarins and associates¹³ used a similar technique to assess reactive hyperemia in revascularized small intestine. Labelled microspheres were injected into the proximal aorta 4 to 10 hours after the induction of intestinal ischemia. Scans were then obtained from externalized bowel. Increased radioactivity was considered a good prognostic sign, indicating viability of the ischemic intestine. Schimmel et al.⁹ reported that intestinal infarction produced in dogs by microsphere embolization could be detected by intra-arterial administration of ^{99m}Tc-pyrophosphate. The radionuclide was injected into the superior mesenteric artery and positive images were obtained 24 hours after induction of ischemia. The delay between induction of ischemia and imaging of ischemic bowel by all of these techniques is incompatible with an early diagnosis of acute intestinal ischemia. Furthermore, these techniques are as invasive as arteriography.

Kressel et al.³ used technetium pyrophosphate to detect intestinal infarction in intussuscepted bowel. The radio-

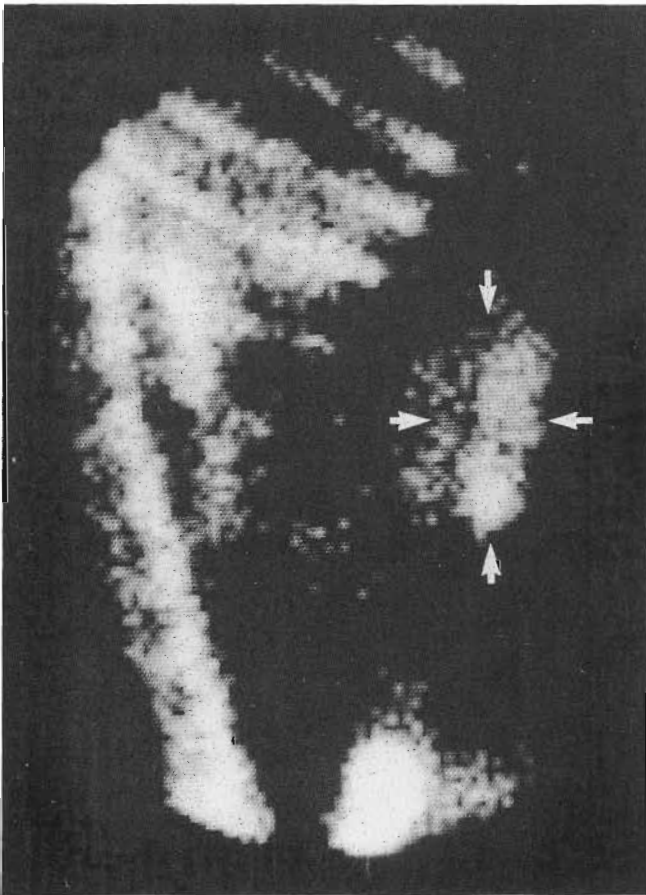


FIG. 5. Scintigraph demonstrating intestinal uptake of radionuclide by a bowel segment subjected to nonocclusive ischemia. This image was obtained 2 hours after the onset of ischemia.

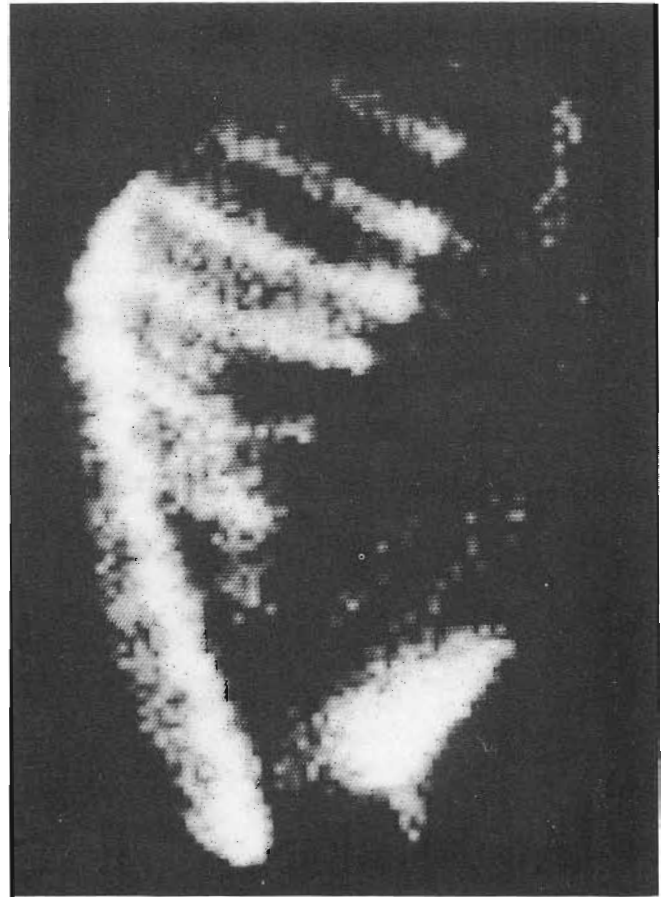

FIG. 6. Control image taken 1 hour after injection of TMDP. Radionuclide uptake is present in the bones and kidneys, but is not observed in the bowel (compare Fig. 5).

nuclide was injected intravenously 24 and 48 hours after creation of an intussusception; animals that had developed infarction demonstrated uptake on scintiscans. Bardfeld et al.¹ used autologous leukocytes labelled with technetium sulfur colloid to detect intestinal ischemia in dogs. The method was based on the observation that ischemic bowel is infiltrated by polymorphonuclear leukocytes. The labelled leukocytes were injected intravenously and successfully identified ischemic intestine in 13 of 15 animals. This method, however, requires preparation of labelled autologous leukocytes and is unable to differentiate inflammatory from ischemic intestinal lesions.

Nonocclusive intestinal ischemia is now recognized as one of the most common vascular ischemic disorders of the bowel.⁶ Arteriography has been the main diagnostic tool in this condition but is subject to significant error,¹¹ and a major dilemma about whether to operate on a patient with cardiac failure and signs of intestinal ischemia frequently arises. We obtained better resolution between ischemic and nonischemic intestinal segments compared

to previous studies because of the apparent greater affinity for ischemic tissues of TMDP compared with other radiopharmaceuticals.^{4,15}

The present study has shown that intestinal ischemia resulting from venous or arterial occlusion, as well as from intestinal strangulation, can be detected in intact animals by external imaging for up to 12 hours after onset, and that nonocclusive intestinal ischemia can be visualized for at least 4 hours after onset. Because of its simplicity and noninvasive nature, radionuclide imaging may have a diagnostic role in the early clinical diagnosis of acute intestinal ischemia.

References

1. Bardfeld PA, Boley SJ, Samartano R, Bontemps R. Scintigraphic diagnosis of ischemic intestine with ^{99m}Tc sulfur colloid-labelled leukocytes. *Radiology* 1977; 124:439.
2. Holman BL, Tanaka TT, Lesch M. Evaluation of radiopharmaceuticals for the detection of acute myocardial infarction in man. *Radiology* 1976; 121:427.
3. Kressel, HY, Moss AA, Montgomery CK, et al. Radionuclide imaging of bowel infarction complicating small bowel intussusception in dogs. *Invest Radiol* 1978; 13:127.
4. Mills LS, Basmadjian PG, Ice DR. Radiopharmaceuticals used in myocardial imaging. *J Pharm Sci* 1981; 70:13.
5. Moossa AR, Skinner DB, Sark V, Hoffer P. Assessment of bowel viability using ^{99m}Tc-tagged albumin microspheres. *J Surg Res* 1974; 16:466.
6. Ockner KR. Vascular diseases of the bowel. In Sleisenger M, Fordtran J, eds. *Gastrointestinal Disease*. Philadelphia: WB Saunders, 1978.
7. Parkey RW, Bunte FJ, Meyere SL, et al. A new method for radionuclide imaging of acute myocardial infarction in humans. *Circulation* 1974; 50:540.
8. Rossman JD, Rouleau JH, Strauss W, Pitt B. Detection and size estimation of acute myocardial infarction using ^{99m}Tc-glucose-heptomate. *J Nucl Med* 1975; 16:980.
9. Schimmel DH, Moss AA, Huffer PB. Radionuclide imaging of intestinal infarction in dogs. *Invest Radiol* 1976; 11:277.
10. Tetalman RM, Foley LC, Spencer PC, Bishop PS. A critical review of the efficacy of ^{99m}Tc pyrophosphate in detecting myocardial infarction in 103 patients. *Radiology* 1977; 124:431.
11. Wittenberg J, Athanasoulis CA, Shapiro JH, Williams LF. A radiologic approach to the patient with acute extensive bowel ischemia. *Radiology* 1973; 106:13.
12. Wynne J, Holman LB. Acute myocardial infarct scintigraphy with infarct-avid radiotracers. *Med Clin North Am* 1980; 64:119.
13. Zarins CK, Skinner DB, Rhodes BA, James FA. Prediction of the viability of revascularized intestine with radioactive microspheres. *Surg Gynecol Obstet* 1974; 138:576.
14. Zimmer MA, Isitman AT, Holmes RA. Enzymatic inhibition of diphosphonate: a proposed mechanism of tissue uptake. *J Nucl Med* 1975; 16:352.
15. Zweiman GF, Holman LB, O'Keefe A, Idoine J. Selective uptake of ^{99m}Tc complexes and ⁶⁷Ga in acutely infarcted myocardium. *J Nucl Med* 1975; 16:975.