

**Current**

# TECHNIQUES in GENERAL SURGERY

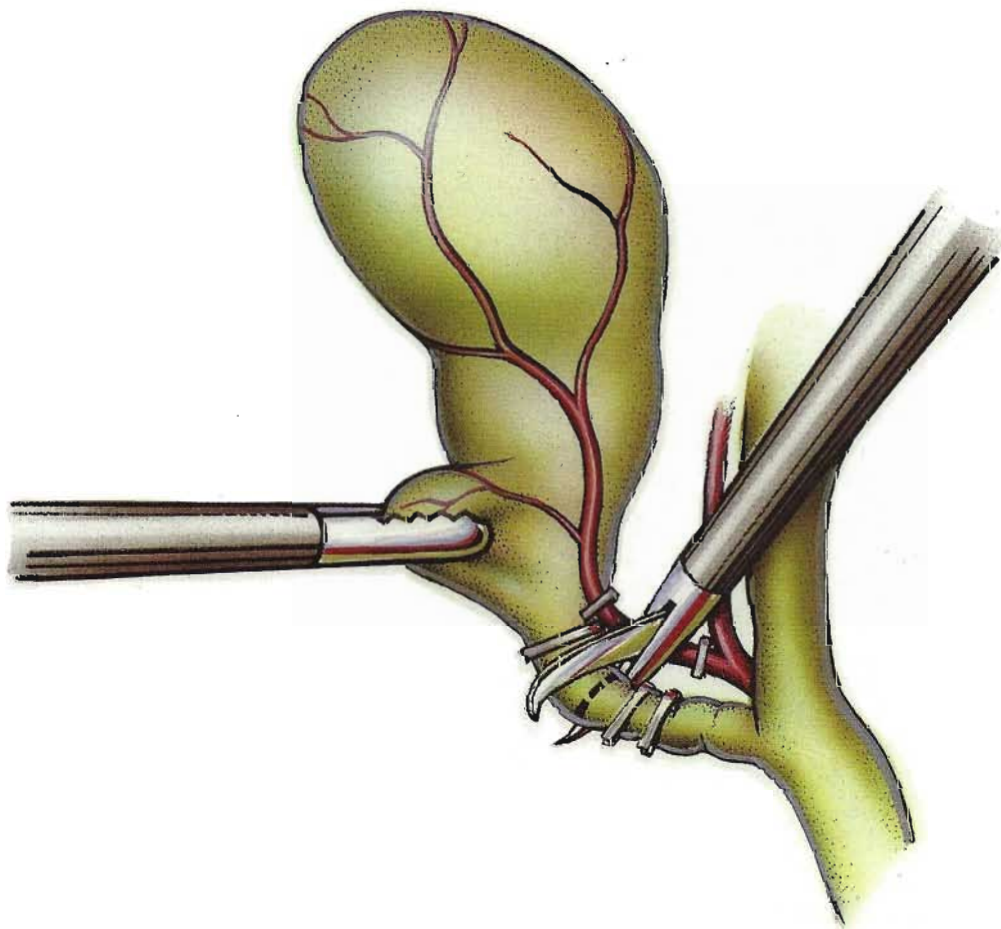
Robert E. Condon, MD, Editor

---

## Laparoscopic Cholecystectomy

**Constantine T. Frantzides, MD, PhD**

Assistant Professor  
Department of Surgery  
Medical College of Wisconsin  
Milwaukee, Wisconsin



**T**he first laparoscopic cholecystectomy was performed in 1987 in France by DuBois.

Since its introduction, the procedure has been widely adopted in both Europe and the United States; indeed, it is the phenomenon of the decade in general surgery. Initial reports are encouraging, but only time will tell if the good results can continue to be duplicated on a widespread basis and if longterm results compare favorably to those obtained with the open technique, particularly as a new generation of surgeons with less developed skills in open cholecystectomy comes to dominate future surgical practice. This article reviews the laparoscopic procedure, with special focus on how to avoid problems.

### Preoperative evaluation and patient selection

Preoperative evaluation of patients for laparoscopic cholecystectomy differs little from that of patients undergoing standard open cholecystectomy. A detailed history is taken to exclude other GI pathology that may mimic cholelithiasis. A careful search is made for indications of choledocholithiasis. A thorough physical examination is then performed. Liver function tests are obtained with particular attention given to serum bilirubin and alkaline phosphatase determinations. Elevation of either suggests the possibility of common-duct pathology, which may change management. Finally, an ultrasound examination is obtained to confirm the presence of gallstones and to evaluate the size of the common bile duct.

In the absence of evidence of choledocholithiasis, the diagnostic workup can stop at this point. For certain other patients, a decision about how to proceed must be made. These include patients with a history of jaundice, pancreatitis, acholic stools, or dark urine; patients with an elevated bilirubin, alkaline phosphatase, or amylase determination; and patients with a dilated extrahepatic biliary tree on radiologic evaluation.

Firm recommendations for dealing with suspected or proven preoperative choledocholithiasis are difficult to make at this point. Options include: (1) preoperative endoscopic retrograde cholangiopancreatography (ERCP) with sphincterotomy and stone extraction followed by laparoscopic cholecystectomy; (2) laparoscopic cholecystectomy with intraoperative

cholangiogram to confirm common-duct stones and a formal, open common bile duct exploration or, alternatively, exploration of the duct laparoscopically; or (3) open cholecystectomy with common bile duct exploration.

Currently, laparoscopic common bile duct exploration should be viewed as

Table

### Contraindications to Laparoscopic Cholecystectomy

#### Relative

- Acute cholecystitis
- Coagulopathy
- Prior upper abdominal operation
- Choledocholithiasis
- Liver disease
- Morbid obesity
- Acute pancreatitis
- Pregnancy

#### Absolute

- Major bleeding disorder
- Portal hypertension, advanced
- Acute cholangitis
- Abdominal sepsis or peritonitis

investigational and not for routine use, although equipment and techniques are available. Open common bile duct exploration is a time-honored, effective, and safe method that is still the standard procedure for managing choledocholithiasis. Untreated common bile duct stones must be evaluated on a patient-by-patient basis.

When first introduced, laparoscopic cholecystectomy had a fairly long list of contraindications, but these have decreased dramatically as experience has been gained. Currently, the procedure has few absolute contraindications, and even these are being modified continuously (Table).

### Operating room design and patient preparation

Laparoscopic cholecystectomy is performed under general anesthesia in a fully equipped operating room under sterile conditions. Instruments for conversion to an open cholecystectomy should be readily available, and the patient's entire abdomen from nipples to pubis is prepped, should conversion to the open procedure be required. Special care should be taken in cleaning the umbilicus, as this is the most common area for wound infection following laparoscopic surgery.

The patient is placed on the operating table in the supine position. Compression stockings or sequential compression devices should be placed on the lower extremities as prophylaxis against deep venous thrombosis.

Laparoscopic cholecystectomy is a team effort. Operating time and technical difficulties are reduced dramatically when the surgeon works with the same assistants on a day-to-day basis. Video monitors placed on both sides of the operating table make it easy for all involved to view the operation and provide the best help. The surgeon operates from the left side of the table, using both hands. The first assistant stands on the patient's right side and is responsible for retraction of the gallbladder, using instruments passed through a lateral subcostal cannula. The camera operator stands below the surgeon.

### Establishing pneumoperitoneum

The first step in performing laparoscopic cholecystectomy, creating a pneumoperitoneum, can be accomplished in several ways. The standard method involves the use of a Veress needle. A 10- to 12-mm curvilinear skin incision is made in the infraumbilical skin fold. The Veress needle is passed through this incision, held in the right hand between the thumb and index finger by the hub so as not to restrict the opening-loaded mechanism. Pressure should be exerted from the wrist, not the shoulder, to prevent sudden uncontrolled penetration of the abdominal wall.

The patient is placed in a slight Trendelenburg position to allow the intestines to migrate cephalad. The needle is directed towards the pelvis and with pressure from the wrist is advanced through the fascia into the abdominal cavity. The surgeon will feel entry through the peritoneum as a "pop." Once the position of the needle within the abdominal cavity is confirmed, the abdomen is filled with gas. Pneumoperitoneum will become evident by distention and loss of percussion dullness over the liver. The intra-abdominal pressure should be kept below 15 mm Hg.

The Veress needle technique is not recommended for patients who have had a previous abdominal operation because adhesions may fix bowel to the anterior abdominal wall, making injury more likely. In these cases we recommend an "open" technique. In fact,

we use the open technique routinely in patients with or without previous surgery. We feel it is safer because no sharp instrument is blindly inserted into the abdomen. Also, because gas is insufflated through a 10- or 11-mm cannula, the open technique provides a rapid pneumoperitoneum.

With the open method, the small incision made in the infraumbilical skin fold is carried down to the fascia. The fascia is incised in the midline and the abdomen entered under direct vision. A finger is placed in the abdomen to check for and clear adhesions. A Hasson-type cannula is then inserted and gas is insufflated through the cannula.

Either a Veress needle puncture or an "open" technique can be used to gain initial entry at other points on the anterior abdominal wall that may be chosen to avoid suspected adhesions from previous surgery. During insufflation, development of high pressure or slow establishment of the pneumoperitoneum indicates a misplaced needle or cannula; the position should be rechecked.

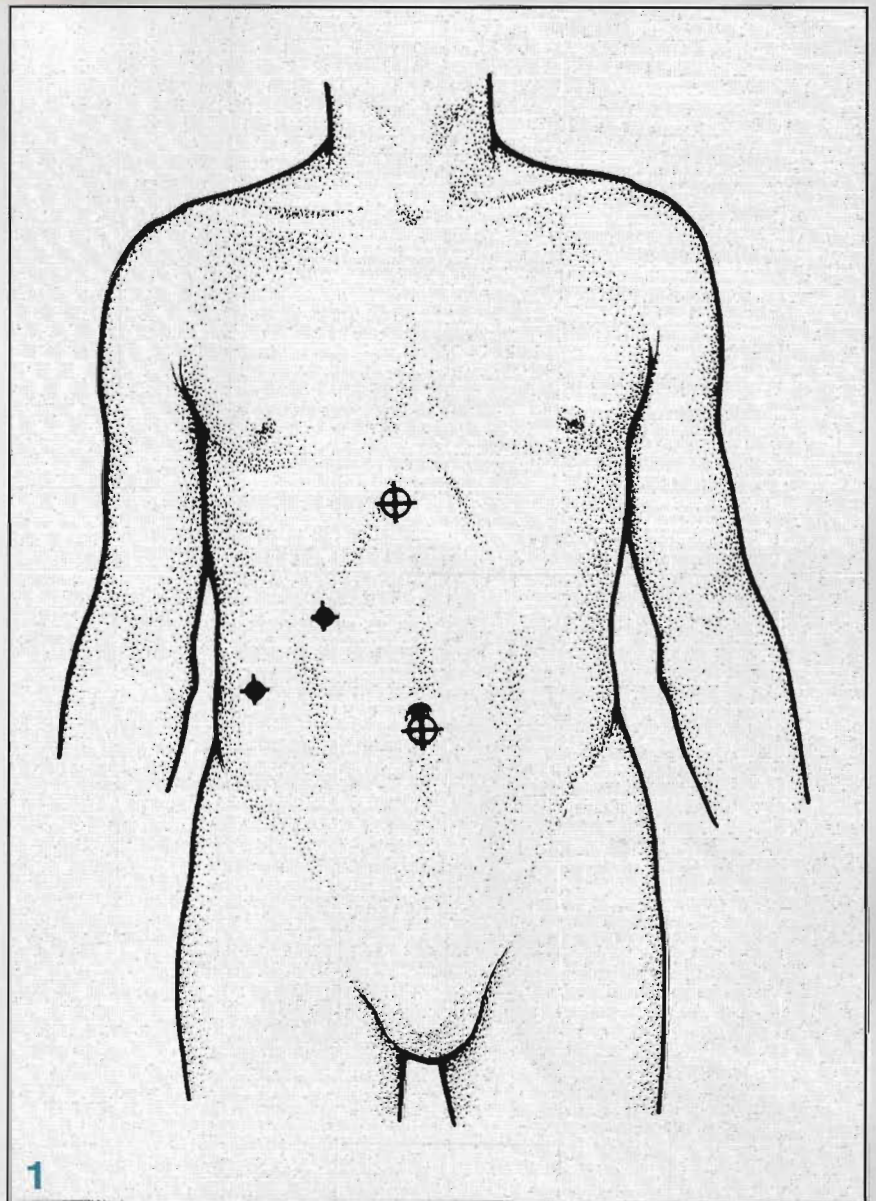
#### Insertion of trocars

After the pneumoperitoneum has been established, additional cannulas are placed to provide access for retraction and dissection. If the open technique was used, the umbilical cannula is already in place and a videolaparoscope is passed through it into the abdomen. If a Veress needle was used, the needle is removed and replaced by a 10- or 11-mm trocar. The trocar is held in the right hand and advanced slowly with a twisting motion. The videolaparoscope is placed through the umbilical cannula and the abdomen is explored.

Initial laparoscopic exploration through the umbilical cannula may reveal adhesions, even in patients without previous surgery. In this case, placement of a second cannula in a safe, open area may allow for adhesiolysis and subsequent safe placement of the needed trocars. A total of four trocars are placed, as shown in Figure 1.

#### Cholecystectomy

After exploration confirms gallbladder pathology and excludes other intra-abdominal processes, removal of the gallbladder can begin. The patient is placed in a 30° reverse Trendelenburg (feet down) position and rotated slightly to the left. These maneuvers shift the

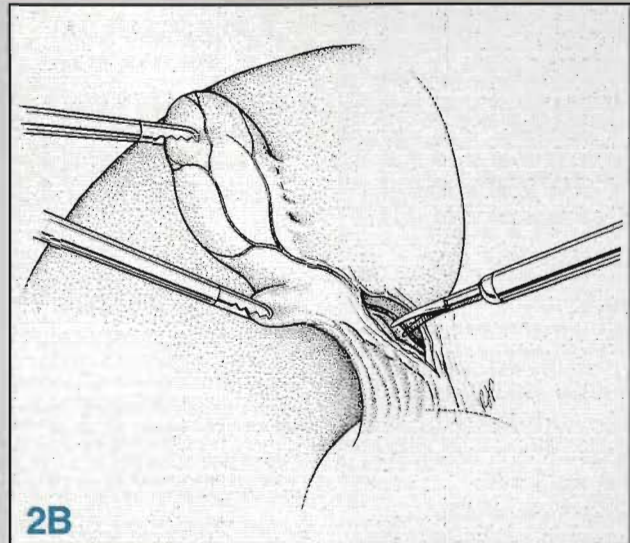
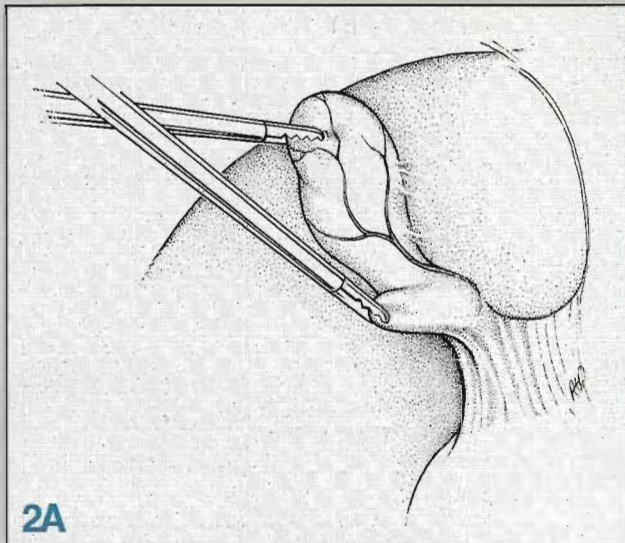


intestines and stomach out of the right upper quadrant and help expose the gallbladder neck and cystic duct.

The first assistant grasps the fundus of the gallbladder with an atraumatic clamp placed through the right lateral cannula, lifting the gallbladder up and pushing it cephalad. A second clamp is then placed through the right subcostal cannula to grasp the neck of the gallbladder, retracting it and exposing the cystic duct. This second grasper is controlled by the surgeon's left hand. With these two clamps, the gallbladder is retracted up and away from the hepatoduodenal ligament, thus exposing the critical structures (Figure 2A). An atraumatic dissector is passed through the subxiphoid cannula, and blunt dissection in the triangle of Calot is begun (Figure 2B). The surgeon's right hand controls the dissection while the left hand provides countertraction.

The cystic artery and duct are identified by blunt dissection and followed to the gallbladder wall to assure that the right hepatic artery is preserved. The cystic artery is ligated proximally and distally, using clips fired from a clip-applier passed through the subxiphoid cannula (Figure 3A). Laparoscopic scissors are used to divide the cystic artery. The cystic duct is isolated and ligated with clips, applied distally, near the gallbladder wall (Figure 3B). At this point a cholangiogram can be performed (to be discussed later) or the procedure can continue.

The proximal duct is then ligated with two clips and divided with scissors (Figure 4A). The gallbladder is dissected from the liver bed by electrocautery (Figure 4B). The dissection begins at the neck of the gallbladder and proceeds anteriorly (superiorly) along the inferior aspect of the liver, to the fundus. Just before the gallblad-



der is completely removed from the liver, the few remaining attachments are used to retract the liver upwards, exposing the gallbladder bed and subhepatic space. This area is irrigated thoroughly and adequate hemostasis is assured. The gallbladder is then detached from the liver and is ready for removal from the abdomen.

The gallbladder is held by the grasper placed through the right lateral cannula. The videolaparoscope is moved to the subxiphoid cannula. A grasper is passed through the umbilical cannula, and the neck of the gallbladder is transferred to this instrument. The gallbladder is pulled up to the umbilical cannula and the specimen and cannula are removed together through the fascial opening.

After the gallbladder is removed, the pneumoperitoneum is released through the cannulas, which are then removed. The fascial opening below the umbilicus is closed with interrupted non-absorbable sutures, and the skin incisions are closed with subcuticular sutures or skin tapes.

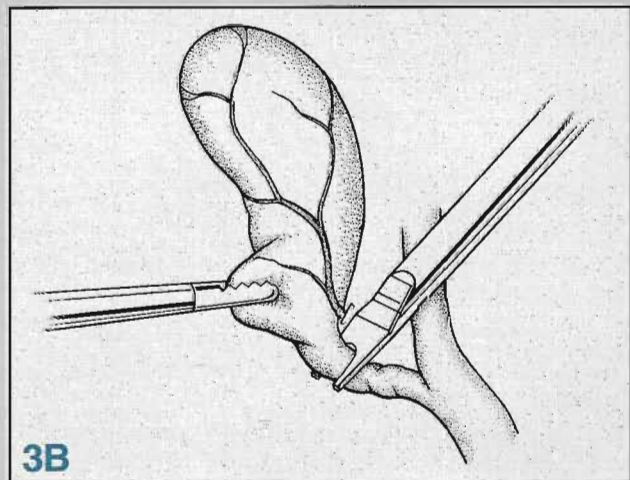
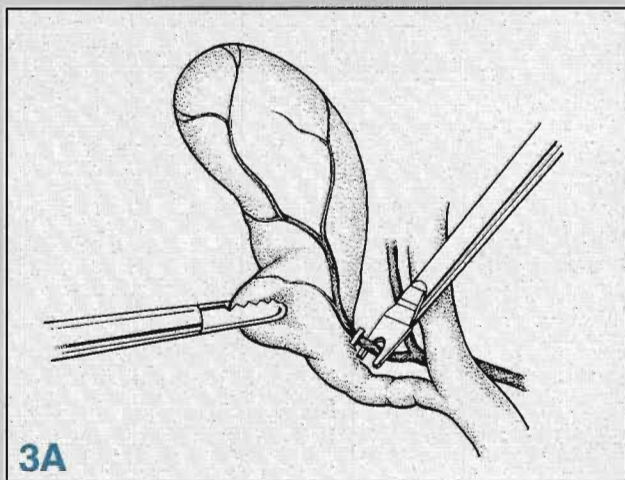
### Cholangiography

There has been much debate in the last two years over routine versus selective use of cholangiography during laparoscopic cholecystectomy. As prime reasons for its use, advocates cite the 5% to 10% of cholangiograms that reveal unsuspected pathology and the fact that most bile duct injuries occur in cases in which a cholangiogram is not used. Detractors point out the added cost, additional operative time, and the number of unnecessary bile duct explorations as reasons for using cholangiography selectively.

A recent study at our institution has shown that selective intraoperative cholangiography, based on pre-operative criteria, does not result in a higher incidence of common bile duct injuries or retained stones than routine cholangiography. However, although an intraoperative cholangiogram may not necessarily prevent common bile duct injury, it can help prevent extension of the injury. Thus, we feel cholangiography should be performed whenever there are uncertainties about the anatomy.

Laparoscopic cholangiography can be performed through either the cystic duct or the gallbladder; studies have shown that injection through the cystic duct is preferable.

After the cystic duct has been dissected, a clip is placed on the distal duct close to the gallbladder, and laparoscopic scissors are used to make a small incision in the duct just proximal to the clip (ie, between the clip and the common duct). A cholangiogram catheter is then guided through the right lateral port into the cystic duct (Figures 5A, B). The catheter can be secured with a clip or held in place with one of a number of specially designed instruments. Balloon-tipped catheters designed specifically for laparoscopic intraoperative cholangiography also are available. Once the catheter is in place, a standard cholangiogram is obtained, using a portable x-ray machine or a portable C-arm fluoroscopic unit. The patient should be taken out of the reverse Trendelenburg position for the cholangiogram so that the proximal biliary tree is well visualized.



**Technical tips**

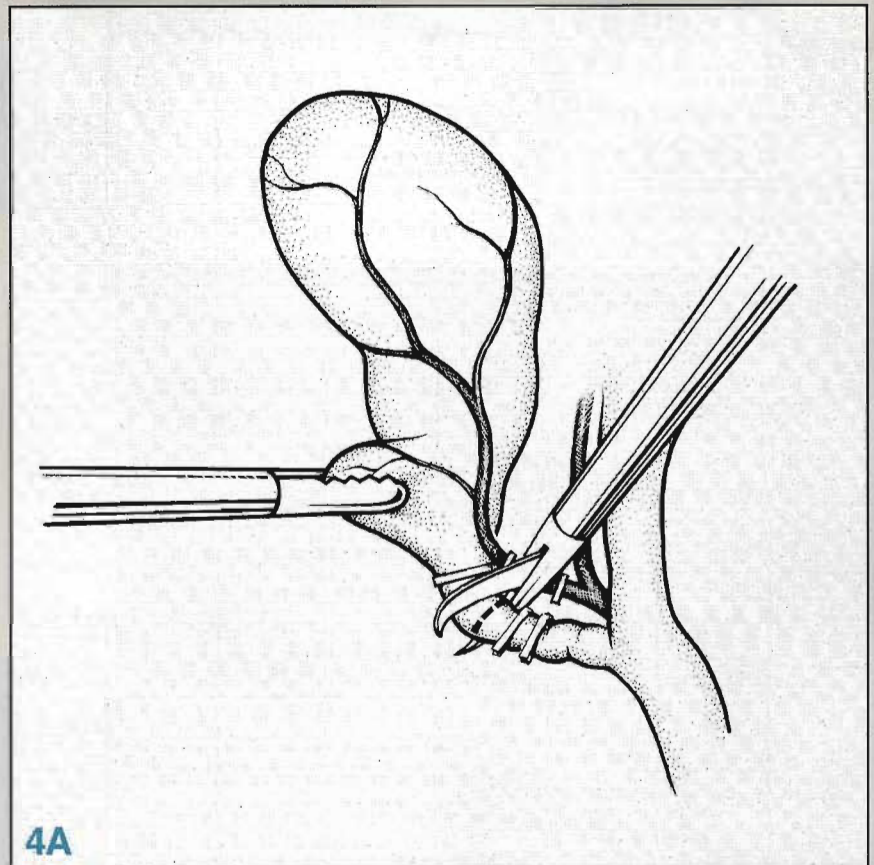
Experience and creativity will help solve most of the problems encountered during laparoscopic cholecystectomy. Common problems and advice for managing them follow:

1. **Difficulty in establishing pneumoperitoneum.** If any difficulty is encountered using the Veress needle, the open method should be used. If adhesions near the umbilicus are suspected or encountered, create the pneumoperitoneum via a puncture at one of the other trocar sites, usually the subxiphoid position. If any uncertainty exists about the location of the umbilical cannula, use the laparoscope through the cannula to confirm the position.

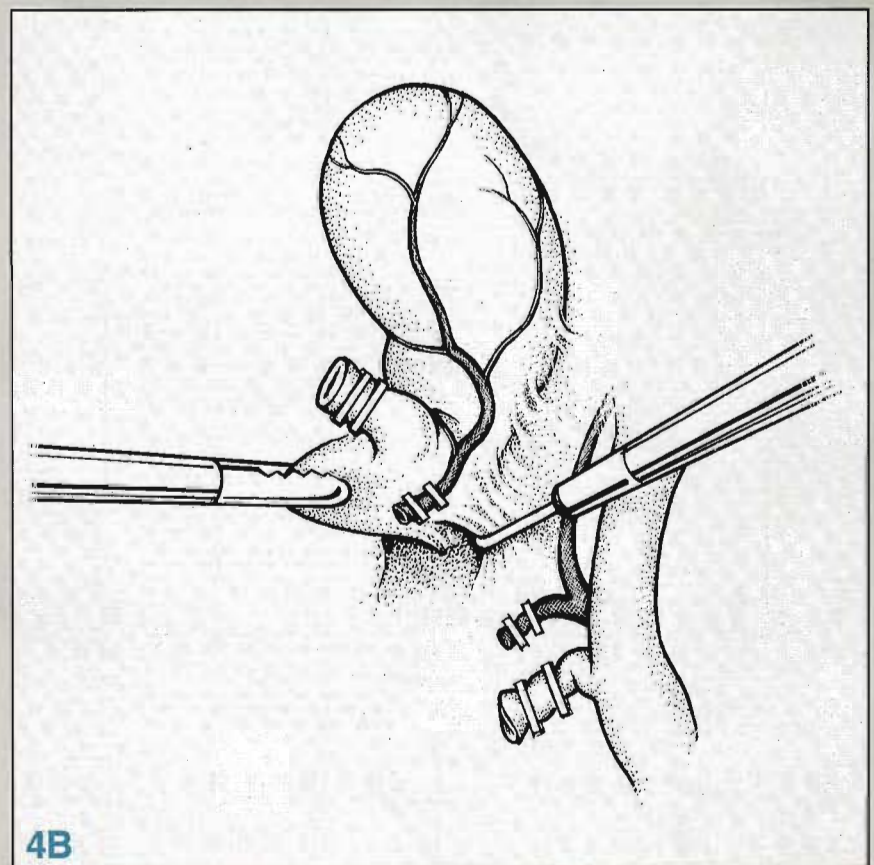
2. **Trocar placement.** Special care should be exercised in placing the subxiphoid trocar. Do not put it through the falciform ligament, as this can cause troublesome bleeding. Bleeding within the ligament, should it occur, can be controlled with clips or by division of the ligament and ligation with pre-tied endosutures. Avoid bleeding at trocar sites by transilluminating the abdominal wall to locate vessels prior to inserting the trocar. A slow twisting motion should be used when inserting trocars. Resistance to placement is usually the result of an inadequate skin incision; make the incision larger.

3. **Problems during cholecystectomy.** Not infrequently the gallbladder is so intensely distended that graspers cannot be applied. In this case, aspirate the gallbladder contents with an endoscopic needle and proceed with the operation. Inadvertent punctures or tears in the gallbladder are not usually a problem. Spilled bile should be aspirated and any spilled stones should be retrieved, if possible. Small holes or tears in the gallbladder can be closed with clips or with an endoloop.

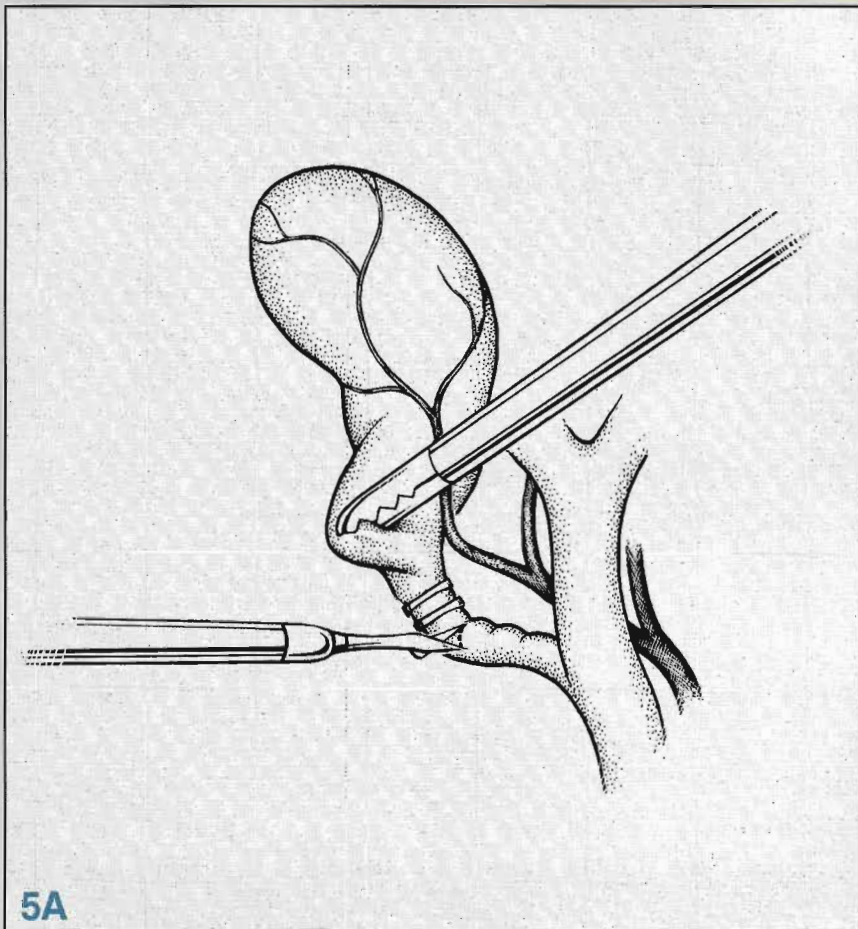
4. **Problems during extraction.** If the gallbladder is too distended with bile or multiple stones to pass easily through the umbilical fascial opening, the neck of the gallbladder is pulled partly up into the umbilical cannula and the cannula and gallbladder are withdrawn to just above the skin. Kelly clamps are then used to grasp and secure the gallbladder. A small incision is



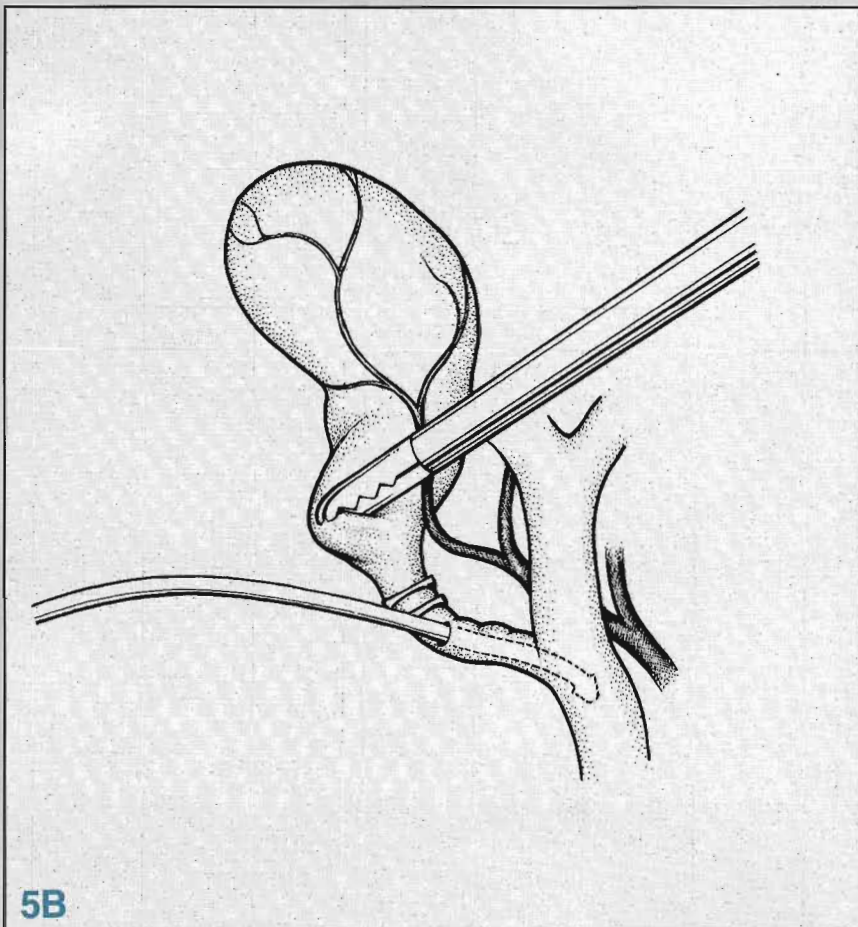
4A



4B



5A



5B

made in the neck of the gallbladder, and bile and stones are aspirated with attention to preventing spillage and contamination of the subcutaneous tissues. The decompressed gallbladder can then be extracted. If extraction is impeded by one or more large stones, the umbilical fascial opening is enlarged to allow removal of the gallbladder.

### Complications

There are few complications specific to laparoscopic cholecystectomy; most intra- and postoperative problems are the same as may occur with traditional open cholecystectomy, although the frequency of specific complications may differ. Most series report morbidity rates of less than 10% and mortality rates of less than 1%. The most frequent complications are hemorrhage, bile duct injury, overlooked or retained common bile duct stones, postoperative bile leak, perihepatic fluid (bile or pus) collections, and infection.

*Bleeding* can be encountered during laparoscopic cholecystectomy at several sites. Bleeding at a trocar site is usually mild and self-limited. Large, deep sutures placed into the abdominal wall during the procedure to encircle and temporarily tamponade bleeders are effective. Bleeding also can be stopped by tamponade using a Foley catheter. Bleeding from the liver is not unusual; it is typically slow and easy to control with cautery. Hemostatic collagen-based sheets can be placed on the raw liver surface to help stop bleeding. Injury to the portal vein and inferior vena cava have been reported; obviously, laparotomy to control bleeding will be necessary in this rare situation.

The most frequent site of troublesome bleeding is the cystic artery; it can appear torrential through the magnified laparoscopic camera but rarely is. Careful dissection will help avoid this complication. The surgeon should remain calm and attempt to grasp the proximal artery to slow the bleeding. The field should then be irrigated, and only after the operator is sure that the cystic artery is indeed the source of bleeding should clips be placed. Dissection of this vessel close to the gallbladder wall will avoid inadvertent ligation and division of an aberrant right hepatic artery. Obviously, inability to obtain adequate hemostasis is an indication for conversion to laparotomy.

*Bile duct injury* is the most feared complication of laparoscopic cholecystectomy. The incidence of this event may be higher with the new approach, but more experience and use of cholangiography whenever in doubt should reduce the incidence. *Meticulous dissection is the key to avoiding mistakes.* Biliary tract anomalies are well recognized, and problems are best averted by using cholangiography. Most common-duct injuries occur when a short cystic duct is present or when the cystic duct courses parallel to the common duct. Inflammation of the gallbladder with dense adhesions may obscure anatomy, thus eluding the surgeon as to the structures dissected. Traction on the gallbladder can distort the common duct and cause anatomic confusion. Before any ductal structure is clipped or divided, it should be traced to the gallbladder by opening the peritoneum on both sides to assure it is the cystic duct.

Management of *retained or overlooked common-duct stones* is no different than with traditional open surgery. Endoscopic sphincterotomy and stone extraction is the best option.

*Bile leaks* have been seen with increasing frequency since the advent of laparoscopic cholecystectomy. Leaks can occur from the liver bed, accessory bile ducts, the cystic duct, or from a missed common-duct injury. Leaks typically present as persistent complaints of abdominal pain that may radiate to the right shoulder and is often associated with abdominal distention, leukocytosis, and fever. Computed tomography usually reveals a perihepatic fluid collection; aspiration of the fluid reveals bile. A percutaneous catheter is placed for drainage. In the absence of distal ductal obstruction, the leak should resolve. If not, ERCP will help to localize the leak, demonstrate any obstruction and, following sphincterotomy, reduce biliary pressure. If signs of peritonitis are present or if the patient deteriorates clinically, immediate operation is indicated.

*Wound infection* appears to be rare after laparoscopic cholecystectomy, probably because of the small size of the incisions. Even if subcutaneous wound infection does occur, it is easily managed by opening the wound, and it rapidly resolves, again because of the small size of the wound.

Preoperative antibiotic prophylaxis is recommended. Additional antibiotic

administration is not usually needed for treating a wound infection, but this decision should be based on clinical circumstances.

### Conversion to open cholecystectomy

The surgeon may elect at any time to convert a laparoscopic cholecystectomy to the open technique if operative findings or the patient's condition do not favor the laparoscopic approach. Common sense must be the guide. Conversion of a laparoscopic cholecystectomy to an open procedure because of laparoscopic findings should not be viewed as a complication or a failure but, rather, should be viewed as an intraoperative surgical decision made in the patient's best interest.

Major bleeding from the cystic artery, hepatic artery, or the gallbladder bed should prompt laparotomy, as should visceral injury at the time of trocar insertion. Bile duct injury is another indication. While acute cholecystitis was once a contraindication to laparoscopic cholecystectomy, this is no longer the case. However, if edema and tissue inflammation make dissection unsafe, conversion to the open technique is indicated. Adhesions in the triangle of Calot or Hartmann's pouch that obscure the common bile duct should also lead to laparotomy. Suspicion of gallbladder or biliary tract cancer, cholecystenteric or choledochenteric fistula, or gangrenous cholecystitis with pericholecystic abscess are further indications for conversion.

### Postoperative care

Most patients can tolerate a liquid diet on the day of operation, and the vast majority can tolerate a regular diet on the first postoperative day. Patients begin ambulation on the day of operation. Postoperative pain is usually minimal. More than 50% of patients require no postoperative narcotic pain medication, and those that do can usually be managed with only oral medications. Some patients complain of right shoulder pain for up to one week after operation; this symptom usually resolves spontaneously. Complete removal of CO<sub>2</sub> at the end of the operation and slow insufflation at the start will decrease this complaint, which is due to trapped subdiaphragmatic gas and diaphragmatic irritation.

More than 90% of patients are discharged within 24 hours of operation and most resume normal activity within one week.

### Conclusion

Laparoscopic cholecystectomy is an exciting new technique. This is the first time in the history of surgery that a procedure has been so widely accepted in such a short time. While only time will tell if this approach will become the standard of care, it appears well on its way to becoming the new "gold standard" for cholecystectomy. The technique is widely applicable. There are very few absolute contraindications. Surgical trauma is minimal and complications of wound healing, pain, infection, and dehiscence have been dramatically reduced. The technique is permanently effective in that it removes the gallbladder, unlike other less invasive techniques that only accomplish stone fragmentation or dissolution. Finally, there are economic advantages over the open technique.

Clearly, it appears that laparoscopy is an advance for general surgery. Reduced postoperative pain, few wound problems, rapid return to normal diet and activity, reduced hospital time, and superior cosmetic results combine to make laparoscopic cholecystectomy a very appealing procedure. ■

### Suggested Reading

- Dubois F, Icard P, Berthelot G, et al: Coelioscopic cholecystectomy: preliminary report of 36 cases. *Ann Surg* 1990;211:60-62.
- Peters JH, Ellison EC, Innes JT, et al: Safety and efficacy of laparoscopic cholecystectomy. *Ann Surg* 1991;213:3-12.
- Ponsky JL: Pitfalls in laparoscopic cholecystectomy. *Prob Gen Surg* 1991;8:320-328.
- Schirmer BD, Edge SB, Dix J, et al: Laparoscopic cholecystectomy: treatment of choice for symptomatic cholelithiasis. *Ann Surg* 1991;213:665-677.
- Southern Surgeons Club: Prospective analysis of 1518 laparoscopic cholecystectomies. *N Engl J Med* 1991;324:1685-1688.
- Spaw AT, Reddick EJ, Olsen DO: Laparoscopic laser cholecystectomy: analysis of 500 procedures. *Surg Laparosc Endosc* 1991;1:2-7.
- Zucker KA, Bailey RW, Gadacy TR, et al: Laparoscopic guided cholecystectomy. *Am J Surg* 1991;161:36-44.



**Robert E. Condon, MD**  
Ausman Foundation Professor  
and Chairman  
Department of Surgery  
Medical College of Wisconsin  
Milwaukee, Wisconsin



**Constantine T. Frantzides, MD, PhD**  
Assistant Professor  
Department of Surgery  
Medical College of Wisconsin  
Milwaukee, Wisconsin

**Artist:**

Robert Demarest



**Current Techniques in  
General Surgery™**  
is a trademark of

Lawrence DellaCorte Publications, Inc.

**Current Techniques in General Surgery™** is published six times a year by Lawrence DellaCorte Publications, Inc., 919 Third Avenue, New York, NY 10022. The opinions or views expressed in the articles are those of the authors and do not necessarily reflect the opinions or recommendations of the publisher or the advertiser.

All inquiries should be addressed to the publisher.

Copyright © 1993 by Lawrence DellaCorte Publications, Inc. No material may be reproduced in whole or in part, in any form, without written permission from the publisher. ISSN 1065-0717

**Robert E. Condon, MD, Editor; Elliot Kurzius, Editor-in-Chief; Doris E. Falk, Special Projects Editor; Stacey Ruhle, Editorial Processing Manager; Elizabeth Doughty, Librarian; Alfred P. Ingegno, Jr., Design Director; Walter J. Biggs, Marketing Consultant; Edward J. Borsa, Marketing Manager; Jamie Polish, Associate Publisher; Lawrence A. DellaCorte, Publisher**