

Brief Clinical Report

Laparoscopic Ladd Procedure and Cecopexy in the Treatment of Malrotation Beyond the Neonatal Period

Constantine T. Frantzides, M.D., Ph.D., F.A.C.S., David J. Cziperle, M.D., M.S.,
Konrad Soergel, M.D., and Edward Stewart, M.D.

Summary: Intestinal malrotation is rarely diagnosed beyond the neonatal period. Detailed gastrointestinal contrast studies are required in establishing the diagnosis. The treatment is surgical and involves lysis of adhesions and bands with or without cecopexy. Here we describe the first laparoscopic procedure for the treatment of malrotation. **Key Words:** Cecopexy—Internal malrotation—Laparoscopy.

In 1932, Dr. William Ladd described duodenal obstruction secondary to peritoneal folds traversing from the cecum to the posterior abdominal wall (1). These "Ladd's bands" are associated with many variations of abnormal intestinal rotation. Clinical appearance usually occurs in infancy as bilious emesis. However, older children may manifest symptoms of recurrent bouts of colicky abdominal pain (2,3). Malrotation occurring beyond childhood is associated with a multiplicity of symptoms and often a delay in diagnosis (3,4).

CASE REPORT

A 38-year-old man had a history of attacks of severe pain in the epigastrium and left upper quadrant that occurred six times during the previous 12 months. The episodes were associated with borborygmi and abdominal bloating. Three episodes were accompanied by vomiting and two were terminated

by a loose bowel movement. The pain reached a crescendo after 4-6 h and maintained a maximal intensity for 1 h. Between these attacks he experienced frequent episodes of mild left upper-quadrant distress; bowel movements remained normal and his weight stable.

His medical history included mild abdominal pain 17 years ago without a diagnosis as well as a right inguinal herniorrhaphy, and excision of a chest wall lipoma.

Evaluation included a normal gallbladder ultrasonographic study as well as a normal sigmoidoscopy. An upper gastrointestinal series and a barium enema demonstrated the ascending colon and cecum to be in the left upper quadrant (Fig. 1) and an absent ligament of Treitz; the small bowel was located in the right side of the abdomen.

The patient refused conventional laparotomy and underwent a laparoscopic Ladd procedure as well as a laparoscopic cecopexy.

TECHNIQUE

Under general endotracheal anesthesia and with the patient in a supine position, a 1.5-cm subumbilical curvilinear incision was made and a Hasson trocar introduced into the abdomen under direct vision. Pneumoperitoneum was achieved with carbon

Received August 16, 1994; accepted October 28, 1994.

From the Departments of Surgery (C.T.F., D.J.C.), Gastroenterology (K.S.), and Radiology (E.S.), Medical College of Wisconsin, Milwaukee, Wisconsin, U.S.A.

Address correspondence and reprint requests to Dr. C. T. Frantzides, Department of General Surgery, Medical College of Wisconsin, 9200 West Wisconsin Avenue, Milwaukee, WI 53226, U.S.A.

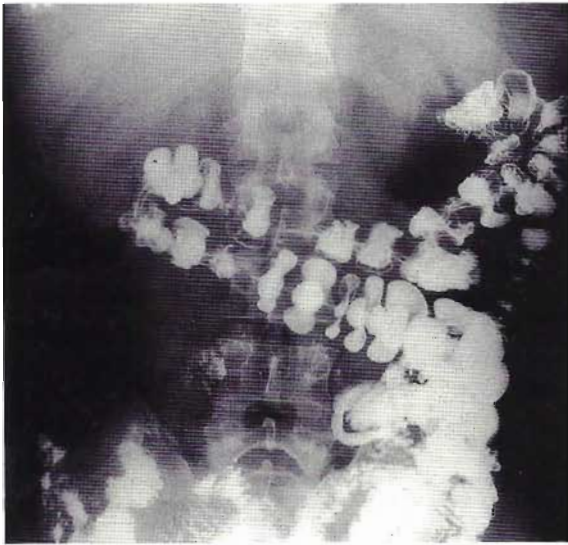


FIG. 1. Barium enema showing the ascending colon and cecum folded up to the transverse colon and located on the left side.

dioxide insufflation and was maintained at a pressure of 13 mm Hg. The abdomen was explored and the right colon was found to be folded up to the left side and adherent to the left colon by multiple translucent avascular bands. A band was also found to be coursing from the posterior abdominal wall across the duodenum to the transverse colon (Ladd's band).

Three additional 10–11-mm trocars were placed, one in the right lower quadrant and two on the left side of the abdomen at the level of the umbilicus. Careful lysis of the bands was performed utilizing sharp and blunt dissection, allowing the right colon to be mobilized into the normal position, with the cecum located in the right lower quadrant. Emphasis was placed on completely lysing the Ladd's bands, especially the portions coursing anterior to the duodenum and down to the transverse colon. A cecopexy was performed by placing five interrupted sutures to the tenia of the right colon and the peritoneum of the right lateral abdominal wall. Total operating time was 1 h 45 min.

RESULTS

Postoperatively, the patient received nonsteroidal anti-inflammatory agents for analgesia and began receiving a liquid diet. He was discharged home on the 1st postoperative day after tolerating a general diet, and released to work in 1 week.

One month postoperatively a barium enema was

performed that demonstrated normal positioning of the colon and cecum (Fig. 2). He has been observed for 3 months and has not had any recurrence of his gastrointestinal symptoms.

DISCUSSION

Congenital duodenal bands are found most commonly in association with abnormalities of rotation. As the embryonic foregut and hindgut return to the abdomen during the 10th week in utero, rotation occurs to cause the gut to lie to the left and posterior to the superior mesenteric artery. The distal ileum, cecum, and colon move anteriorly and to the right. Failure of these rotations results in an abnormal cecal position and peritoneal bands, usually extending from the cecum to the right upper quadrant, across the duodenum (5).

The diagnosis of malrotation beyond the neonatal period is difficult because of the wide variety of symptoms associated with this condition (3,4). Cases with or without emesis should be evaluated with an upper gastrointestinal and small bowel series as well as a barium enema. Asymptomatic patients in whom malrotation is diagnosed serendipitously should undergo surgery to correct the malrotation. Acute midgut volvulus with infarction can

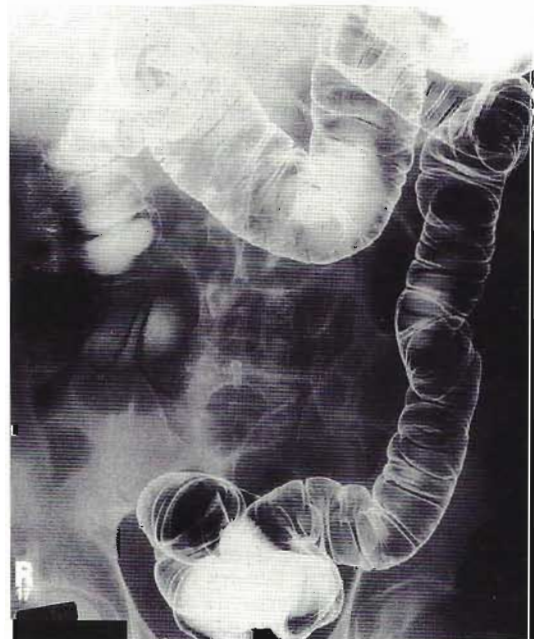

FIG. 2. Postoperative double-contrast barium enema demonstrating the ascending colon and cecum located in the right hemi-abdomen.

occur and is well documented by several authors (3,4,6).

We have demonstrated that lysis of Ladd's bands as well as a cecopexy can be carried out laparoscopically for the treatment of malrotation. The laparoscopic approach has all the advantages of minimally invasive surgery.

REFERENCES

1. Ladd WE. Congenital obstructions of the duodenum in children. *N Engl J Med* 1932;206:277.
2. Raffensperger JG. *Swenson's pediatric surgery*. Norwalk: Appleton & Lange, 1990:518.
3. Powell DM, Otherson HB, Smith CD. Malrotation of the intestines in children: the effect of age on presentation and therapy. *J Pediatr Surg* 1989;24:777.
4. Spigland N, Brandt ML, Yazbeck S. Malrotation presenting beyond the neonatal period. *J Pediatr Surg* 1990;25:1139.
5. Bailey PV, Tracy TF, Connors RH, Mooney DP, Lewins JE, Weber TR. Congenital duodenal obstruction: a 32-year review. *J Pediatr Surg* 1993;28:92.
6. Firor HV, Steiger E. Morbidity of rotational abnormalities of the gut beyond infancy. *Cleve Clin Q* 1983;50:303.