

Brief Clinical Report

Control of Venous Hemorrhage during Laparoscopic Adrenalectomy: A Case Report

MARK A. CARLSON, M.D., and CONSTANTINE T. FRANTZIDES, M.D.

ABSTRACT

An injury to a side branch of the inferior vena cava (IVC) was incurred during laparoscopic right adrenalectomy. The hemorrhage was controlled with the aid of a laparoscopic balloon retractor, and laparotomy was avoided.

INTRODUCTION

MINIMALLY INVASIVE ADRENALECTOMY is feasible,¹⁻⁴ and it may benefit the patient with a shorter recovery period.^{2,3} Some authors have reported conversion to an open procedure to control hemorrhage in the adrenal bed.^{3,4,5} Cause of this hemorrhage was reported to be clip dislocation, renal capsular tear, inferior adrenal vein tear, and right-sided inferior vena cava (IVC) tear. Herein we report a case of hemorrhage from a vena caval injury that was controlled laparoscopically.

CASE REPORT

A 56-year-old woman with hypertension difficult to manage medically was found to have a 2-cm right adrenal mass, which was determined to be an aldosteronoma. It was elected to perform a laparoscopic right adrenalectomy. Under general anesthesia with the patient in left-side-down decubitus position and the table flexed to expose the right flank, pneumoperitoneum was established. Four 10-mm trocars were used. The peritoneal attachments of the liver were taken down from lateral to medial; an inflatable bal-

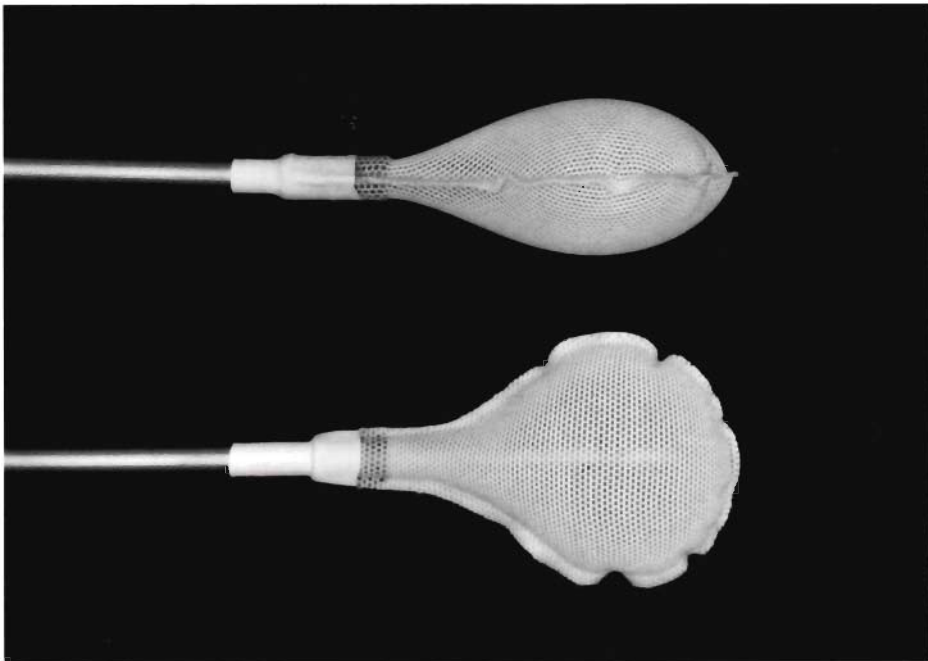


FIG. 1. Ninety degree views of the laparoscopic inflatable balloon retractor. The balloon is covered with a nylon mesh. Balloon capacity = 20 cc. Inflated dimensions = $5.5 \times 4.0 \times 2.0$ cm.

loon retractor (SoftWand[®], Circon Cabot, Santa Barbara, CA; Fig. 1) was used to retract the liver. The IVC and the right adrenal gland were easily identified. The superior and lateral attachments of the gland were divided with electrocautery. The venous drainage on the medial side of the gland was interrupted with hemostatic clips. The inferior portion of the gland then was dissected from the superior pole of the right kidney. During the latter dissection brisk bleeding was noted from the lateral caval region. The IVC was tamponaded at the bleeding site with the balloon retractor (Fig. 2). The remaining attachments to the gland were divided, and the specimen was put into a plastic bag and removed from the abdomen. Because the first balloon retractor was compressing the IVC, a second balloon retractor was inserted through an existing trocar site to retract the liver. It was determined that the bleeding point was a branch of the IVC. Proximal and distal ligation of this vessel was accomplished by several sequences of removing the retractor, applying a clip, replacing the retractor against the bleeding site, and aspirating the field clear. Blood loss during this portion of the procedure was approximately 100 cc. Total blood loss was approximately 500 cc. The patient's postoperative course was uncomplicated. The pathology of the specimen was consistent with an aldosteronoma.

DISCUSSION

We injured a branch on the right side of the vena cava while we were dissecting the right adrenal gland from the superior pole of the kidney. The uniqueness of this case was the ability to tamponade the bleeding vessel with the inflatable balloon retractor. This allowed us to remove the specimen, clean the operative field, and ligate the bleeding vessel, all in controlled fashion. The balloon retractor provides a relatively large surface area to apply pressure to a bleeding site, much as one would use a laparotomy pad in an open procedure. We have found the performance of the balloon retractor laudable in this and other circumstances, and recommend its use where atraumatic retraction/compression is required.

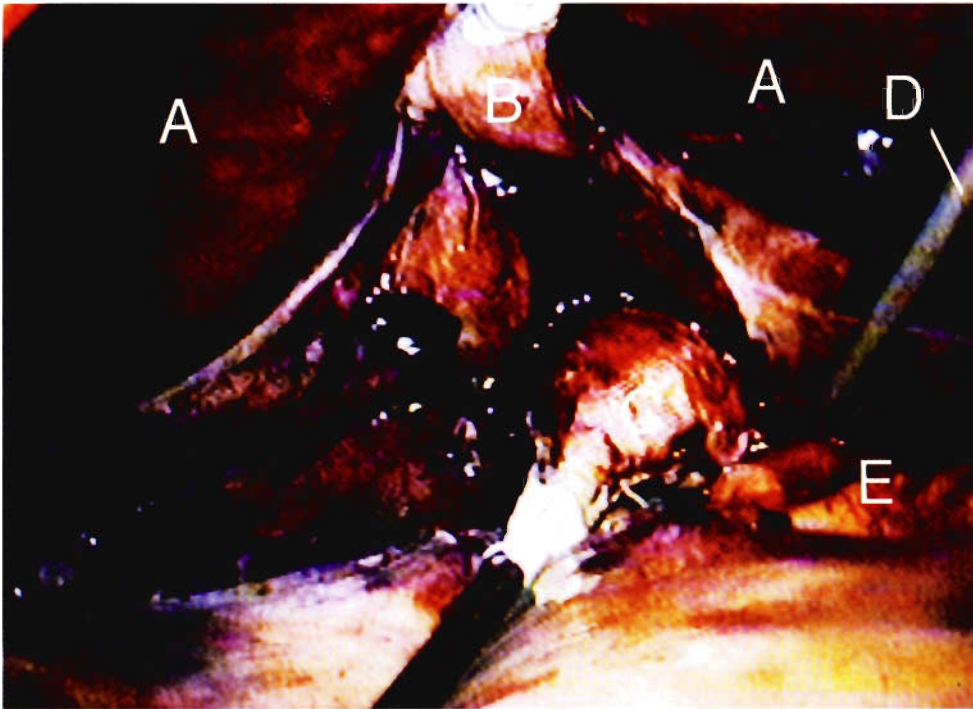


FIG. 2. Tamponade of the bleeding inferior vena cava (IVC) side branch with the laparoscopic inflatable balloon retractor. (A) Liver; (B) Balloon retractor retracting the liver; (C) Balloon retractor compressing the IVC; (D) 5-mm irrigation/aspiration instrument; (E) IVC.

REFERENCES

1. Gagner M, Lacroix A, Prinz RA, Bolte E, Albala D, Potvin C, Hamet P, Kuchel O, Querin S, Pomp A: Early experience with laparoscopic approach for adrenalectomy. *Surgery* 1993;114:1120–1125.
2. Guazzoni G, Montorsi F, Bocciardi A, Da Pozzo L, Rigatti P, Lanzi R, Pontiroli A: Transperitoneal laparoscopic versus open adrenalectomy for benign hyperfunctioning adrenal tumors: a comparative study. *J Urol* 1995;153:1597–1600.
3. Prinz RA: A comparison of laparoscopic and open adrenalectomies. *Arch Surg* 1995;130:489–494.
4. Suzuki K, Kageyama S, Ueda D, Ushiyama T, Kawabe K, Tajima A, Aso Y: Laparoscopic adrenalectomy: clinical experience with 12 cases. *J Urol* 1993;150:1099–1102.
5. Takeda M, Go H, Imai T, Nishiyama T, Morishita H: Laparoscopic adrenalectomy for primary aldosteronism: report of initial ten cases. *Surgery* 1994;115:621–625.

Address reprint requests to:
 Constantine T. Frantzides, M.D., Ph.D., F.A.C.S.
 Associate Professor, Department of Surgery
 Director, Minimally Invasive Surgery Center
 Medical College of Wisconsin
 9200 West Wisconsin Avenue
 Milwaukee, Wisconsin 53226