

Brief Clinical Report

Laparoscopic Jaboulay Gastroduodenostomy for Gastric Outlet Obstruction: A Case Report

CONSTANTINE T. FRANTZIDES, M.D., Ph.D., F.A.C.S., and
MARK A. CARLSON, M.D.

ABSTRACT

A case of gastric outlet obstruction secondary to peptic ulcer disease was treated with laparoscopic truncal vagotomy and Jaboulay gastroduodenostomy. The technique is described.

INTRODUCTION

ONE HUNDRED YEARS AGO Jaboulay described a technique of gastroduodenostomy which today carries his name.^{1,2} In conjunction with either a truncal or proximal gastric vagotomy, the procedure is used to relieve gastric outlet obstruction secondary to cicatricial obstruction of the pylorus.^{2,3,4} Described below is such a case of complicated peptic ulcer disease that was treated laparoscopically with a truncal vagotomy and Jaboulay gastroduodenostomy.

CASE REPORT AND TECHNIQUE

A 54-year-old man with a 10-yr history of duodenal ulcer disease experienced postprandial emesis of undigested food and a 10-kg weight loss for 6 months prior to admission. On physical examination the patient had mild wasting and no palpable abdominal mass. Radiographic examination of the upper gastrointestinal tract with barium contrast revealed a near total gastric outlet obstruction secondary to a pyloric stricture. Complete blood count and electrolytes were normal. The patient was treated initially with nasogastric tube decompression and hydration for 48 h. It was elected to perform laparoscopic vagotomy and gastroduodenostomy.

Neomycin sulfate (1 g) and erythromycin (1 g) were given per nasogastric tube, and cefotetan (2-g IV) was given prior to induction of general anesthesia. The patient was placed in reverse Trendelenburg with the lower extremities in stirrups, and the surgeon stood between the legs. Five 10-mm trocars were placed: left upper quadrant, subxiphoid, supraumbilical, and right upper quadrant (two). The left lobe of the liver was retracted with an inflatable balloon retractor (SoftWand, Circon Cabot, Santa Barbara, CA). The phrenoesophageal ligament was incised, and the lower 5 cm of the esophagus was mobilized bluntly with pal-

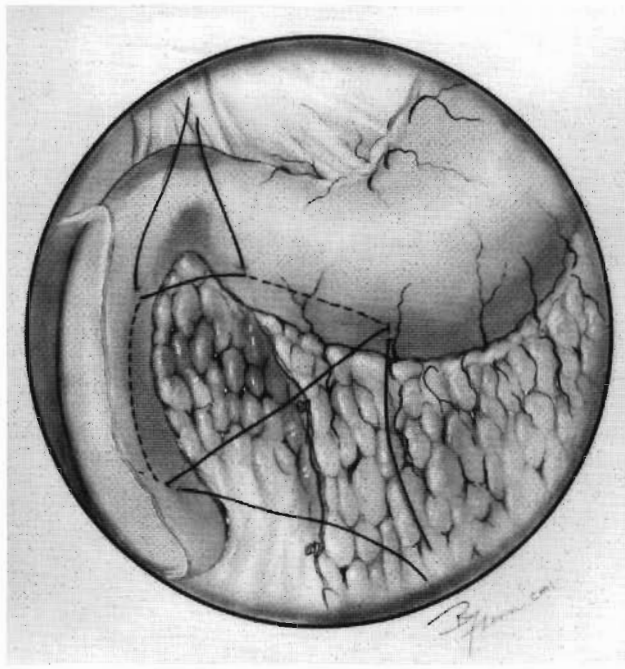


FIG. 1. Stay suture placement for laparoscopic Jaboulay gastroduodenostomy. The duodenum has been mobilized with a Kocher maneuver.

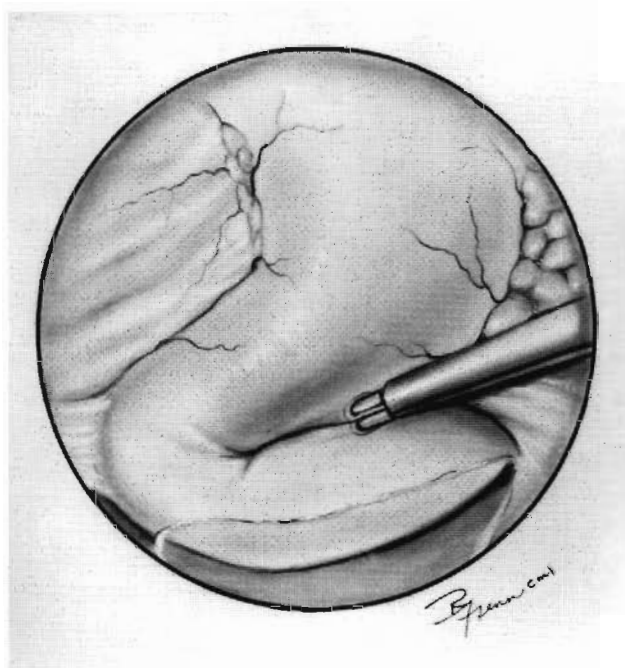


FIG. 2. Insertion of a 6-cm linear cutter through a gastrotomy and a duodenotomy to create the gastroduodenostomy. The stay sutures have been omitted from the figure for clarity.

LAPAROSCOPIC GASTRODUODENOSTOMY

pation probes. The anterior and posterior trunks of the vagus were isolated, clipped, and a 1-cm length of each trunk was excised for pathologic examination.

A Kocher maneuver was performed to allow the duodenum to come in apposition to the stomach. Two stay sutures were placed, with bites into the anterior duodenum and gastric antrum (Fig. 1). A duodenotomy and a gastrotomy then were performed superiorly to the inferior stay suture. The 10-mm trocar in the medial left upper quadrant was exchanged for an 18-mm trocar. A 6-cm linear cutter (Ethicon, Inc., Cincinnati, OH) then was inserted through the 18-mm trocar and into the duodenotomy and gastrotomy (Fig. 2). While the stay sutures were pulled posteriorly, the linear cutter was levered anteriorly to avoid the ampulla. The stapler was fired and removed, and single-layer closure of the duodenotomy and gastrotomy was performed with interrupted full-thickness sutures of 2-0 polyester (Fig. 3). The needle driver was placed through the 18-mm trocar (with a 5-mm adapter), and the grasper went through the right upper quadrant trocar.

Postoperatively the patient remained on nasogastric suction for 2 days, and was given fluids on postoperative day 3. He was discharged on postoperative day 4 on a restricted diet. There were no perioperative complications. A barium meal 3 months later revealed both a patent anastomosis and pylorus. The patient is well and is gaining weight.

DISCUSSION

A patient with benign pyloric stenosis was treated with laparoscopic truncal vagotomy and Jaboulay gastroduodenostomy. This is possibly the first report of a laparoscopic Jaboulay gastroduodenostomy. By avoiding the pylorus and bulb, the Jaboulay procedure is useful in the patient with severe scarring in the pyloroduodenal region.² The truncal vagotomy was the personal preference of the surgeon; others may have preference for a proximal gastric vagotomy.^{3,4} There have been numerous reports of laparoscopic vagotomy.⁵⁻⁷

Laparoscopic procedures involving gastric anastomosis have been reported for Billroth I gastrectomy^{8,9} and gastrojejunostomy.¹⁰ The anastomosis in these reports was created with a circular end-to-end anasto-

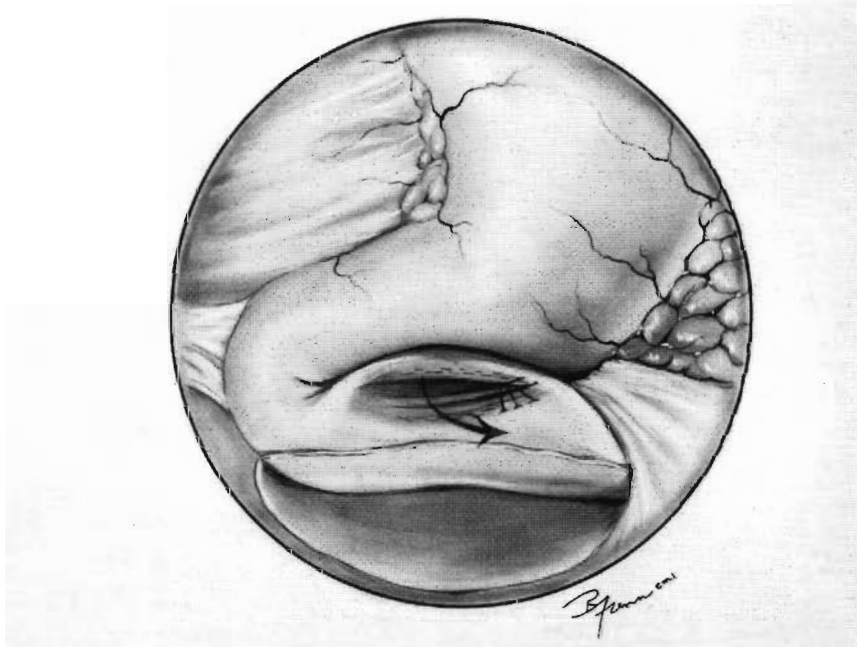


FIG. 3. The completed gastroduodenostomy. The stapler has been fired and removed, and the gastrotomy and the duodenotomy have been closed with sutures.

mosis stapler inserted through a gastrotomy. The gastrotomy was closed with a linear stapler. Our Jaboulay gastroduodenostomy was made with a linear stapler so as to avoid the ampulla. Intracorporeal suturing then was required to close the gastrotomy and duodenotomy used by the stapler.

With the availability of effective medical treatment for peptic ulcer disease, the elective operation for peptic ulcer has all but vanished. Reports of laparoscopic vagotomy have small numbers compared to the reports of laparoscopic cholecystectomy, fundoplication, and herniorrhaphy. Currently the ulcer patient requiring an operation represents a failure of medical therapy (as our patient did). It will be important to maintain an armamentarium of procedures for complicated peptic ulcer disease; many of these procedures can and should be performed laparoscopically.

REFERENCES

1. Jaboulay M: La gastroenterostomie de la jejunoduodenostomie la resection du pylore. Arch Prov Chir (Paris) 1892;1:1.
2. Sawyers JL Jr: Vagotomy and pyloroplasty. In Zuidema GD (ed): Shackelford's Surgery of the Alimentary Tract, vol II, 3rd ed. Philadelphia: W.B. Saunders Co., 1991, pp. 136-148.
3. Dittrich K, Blauensteiner W, Schrutka-Kolbl C, Hoffer F, Armbruster C, Vavrik J: Highly selective vagotomy plus Jaboulay: a possible alternative in patients with benign stenosis secondary to duodenal ulceration. J Am Coll Surg 1995;180:654-658.
4. Donahue PE, Yoshida J, Richter HM, Liu K, Bombeck CT, Nyhus LM: Proximal gastric vagotomy with drainage for obstructing duodenal ulcer. Surgery 1988;104:757-764.
5. Frantzides CT, Ludwig KA, Quebbeman EJ, Burhop J: Laparoscopic highly selective vagotomy: technique and case report. Surg Laparosc Endosc 1992;2:348-352.
6. Dallemagne B, Weerts MM, Jhaes C, Markiewicz S, Lombard R: Laparoscopic highly selective vagotomy. Br J Surg 1994;81:554-556.
7. Laws HL, McKernan JB: Endoscopic management of peptic ulcer disease. Ann Surg 1993;217:548-556.
8. Uyama I, Ogiwara H, Takahara T, Kato Y, Kikuchi K, Iida S: Laparoscopic Billroth I gastrectomy for gastric ulcer: technique and case report. Surg Laparosc Endosc 1995;5:209-213.
9. Nagai Y, Tanimura H, Takifuji K, Kashiwagi H, Yamoto H, Nakatani Y: Laparoscopic-assisted Billroth I gastrectomy. Surg Laparosc Endosc 1995;5:281-287.
10. Sosa JL, Zalewski M, Puente I: Laparoscopic gastrojejunostomy technique: case report. J Laparoendosc Surg 1994;4:215-220.

Address reprint requests to:
Constantine T. Frantzides, M.D., Ph.D., F.A.C.S.
Associate Professor, Department of Surgery
Director, Minimally Invasive Surgery Center
Medical College of Wisconsin
9200 West Wisconsin Avenue
Milwaukee, Wisconsin 53226