

## Prosthetic reinforcement of posterior cruroplasty during laparoscopic hiatal herniorrhaphy

C. T. Frantzides, M. A. Carlson

Department of Surgery, Medical College of Wisconsin, 9200 West Wisconsin Avenue, Milwaukee, WI 53226, USA

Received: 5 March 1996/Accepted: 3 June 1996

**Abstract.** Symptomatic gastroesophageal reflux after Nissen fundoplication may occur if the wrap herniates into the thorax. In an attempt to prevent recurrent hiatal hernia we employed polytetrafluoroethylene (PTFE) mesh reinforcement of posterior cruroplasty during laparoscopic Nissen fundoplication and hiatal herniorrhaphy. Three patients with symptomatic gastroesophageal reflux and a large ( $\geq 8$  cm) hiatal defect underwent laparoscopic posterior cruroplasty and Nissen fundoplication. The cruroplasty was reinforced with a PTFE onlay. No perioperative complications occurred, and in follow-up ( $\leq 11$  months) the patients are doing well. When repairing a large defect of the esophageal hiatus during fundoplication, the surgeon may consider reinforcement of the repair with PTFE mesh.

**Key words:** Laparoscopic Nissen fundoplication — Gastroesophageal reflux — Hiatal hernia — Polytetrafluoroethylene — Prosthetic — Antireflux procedure

After several years of follow-up, the success of laparoscopic Nissen fundoplication in controlling the symptoms of gastroesophageal reflux (GER) appears to be 80–90% [5, 6, 7, 10]. A possible mechanism of Nissen fundoplication failure is herniation of the stomach and wrap into the chest [11], which can produce recurrent reflux. We have noted failure of laparoscopic Nissen fundoplication in some patients who had a large defect ( $>8$  cm) of the esophageal hiatus repaired with posterior cruroplasty. Subsequent barium meal in these patients confirmed a recurrent hiatal hernia with demonstrable reflux. In an attempt to prevent reherniation of the stomach into the chest, we reinforced the posterior cruroplasty with polytetrafluoroethylene (PTFE) onlay in the next patients with large hiatal hernia. Here we report laparoscopic Nissen fundoplication with mesh reinforcement of

posterior cruroplasty in three patients with symptomatic GER and large hiatal hernia.

### Case reports

Our technique of laparoscopic Nissen fundoplication and posterior cruroplasty follows a previous description [5]. Cefazolin (2 g IV) is given with induction of general anesthesia. Carbon dioxide pneumoperitoneum and five 10-mm trocars are used. The lesser omentum and phrenoesophageal ligament are incised, a 50 Fr bougie is placed within the esophagus, and a window is created posterior to the esophagus with blunt dissection. The hiatal hernia is reduced with sharp and blunt dissection of the hernia sac and with gentle traction on the stomach. The short gastric vessels are ligated with a right-angle clip applier or an ultrasonic scalpel (Ethicon). The esophagus is circumferentially mobilized until the lower 5 cm is intrabdominal.

A typical hiatal hernia for which mesh only was utilized is shown in Fig. 1. Prior to the onlay posterior cruroplasty is performed with interrupted sutures of 2-0 polyester into the right and left bundles of the right crus, ensuring that full-thickness bites are taken.

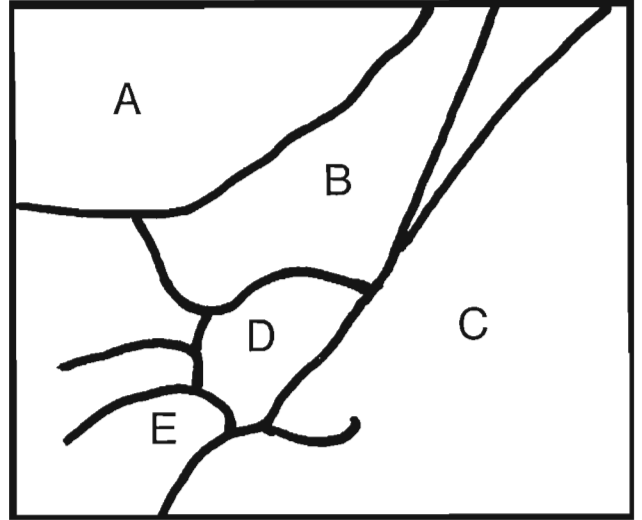
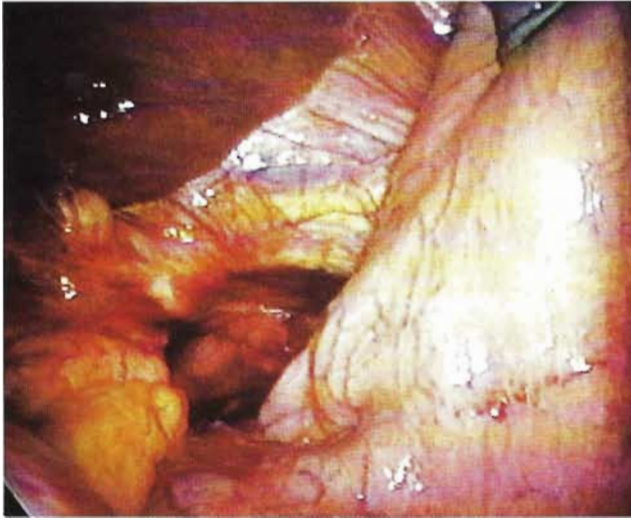
The mesh onlay is an oval sheet ( $15 \times 10 \times 0.1$  cm) of fenestrated PTFE (MycroMesh GoreTex, W. L. Gore and Associates). A radial slot with a 3-cm defect in the center ("keyhole") is cut into the mesh. The mesh is pushed through a 10-mm trocar into the peritoneal cavity and placed around the gastroesophageal junction with the esophagus coming through the 3-cm defect and the radial slot oriented anteriorly (Fig. 2). The PTFE is stapled to the diaphragm with a straight hernia stapler (Ethicon); the two leaves of the keyhole are stapled to each other.

Finally, a 3-cm-long 360° fundoplication is created loosely around the 50 Fr bougie with three sutures of 2-0 polyester, taking bites of stomach wall only (Fig. 3). The most cephalad stitch incorporates the mesh and the anterior arch of the right crus.

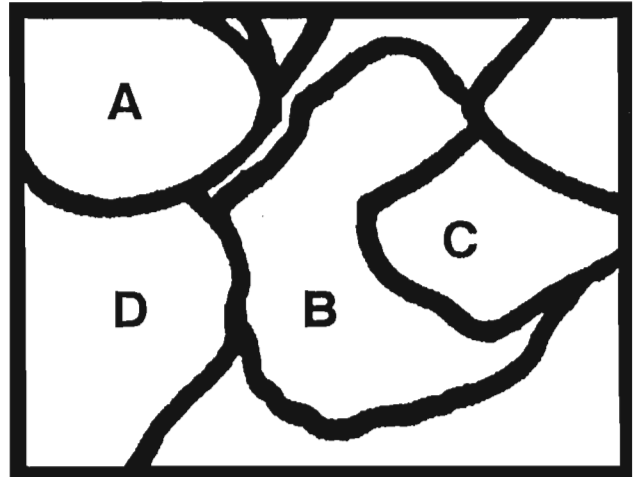
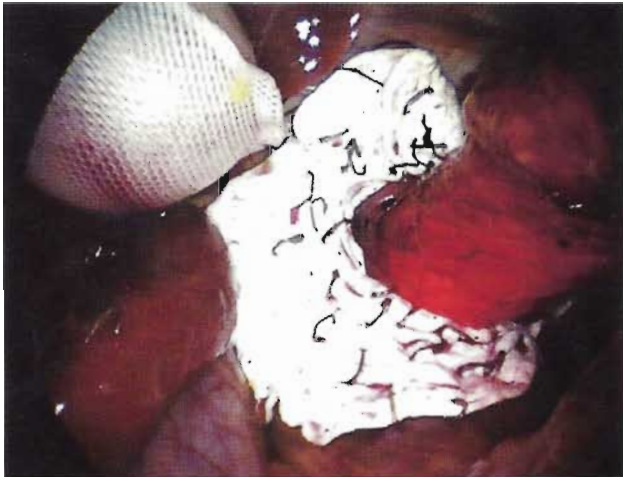
This procedure was performed on three patients who all had severe heartburn, reflux, a partially intrathoracic stomach, and an esophageal hiatus  $\geq 8$  cm in diameter. No perioperative complications occurred. At 5, 16, and 18 months of follow-up the patients are doing well and either barium meal or endoscopy has confirmed a successful operation in each.

### Discussion

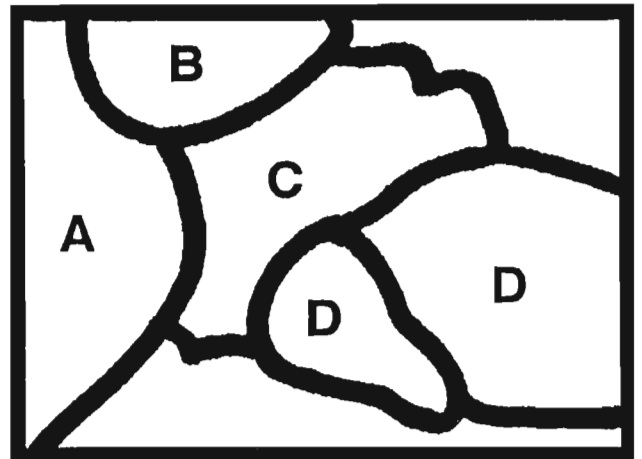
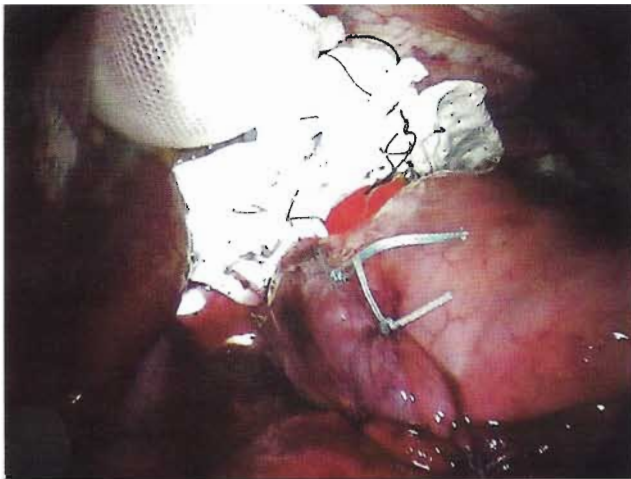The cause(s) of recurrent reflux after an antireflux procedure may be revealed by examining the reoperation for reflux. In one series of 87 patients undergoing operation for a failed antireflux procedure, 72% had recurrent hiatal hernia [11]. Despite the problem of recurrence, the technique of



**Fig. 1.** Intraoperative view of an enlarged esophageal hiatus which was repaired with posterior cruroplasty and PTFE onlay. (A) liver, (B) diaphragm, (C) stomach, (D) esophageal hiatus, (E) gastrohepatic omentum.



**Fig. 2.** Intraoperative view of the hiatus after posterior cruroplasty and PTFE onlay, but before the fundoplication: (A) inflatable balloon retractor, (B) PTFE stapled to diaphragm, (C) esophagus, (D) liver.



**Fig. 3.** Intraoperative view after completion of Nissen fundoplication: (A) liver, (B) inflatable balloon retractor, (C) PTFE stapled to diaphragm, (D) fundoplication.

hiatal herniorrhaphy has not changed appreciably since its inception. Cruroplasty has been done by suturing the crura with 0 or 2-0 nonabsorbable material anterior and/or posterior to esophagus [12]. Cuschieri et al. [3] has reported eight patients with large hiatal hernia who were treated with laparoscopic posterior cruroplasty, with a good short-term result.

Precedent for the use of prosthetic at the esophageal hiatus is limited; one example is the Angelchik and Cohen prosthesis [1], a C-shaped ring of silicone gel contained in a silicone elastomer shell which is placed around the gastroesophageal junction. The enthusiasm for this device was ended by reports of complications of prosthesis migration, luminal penetration, and dysphagia [2]. The indication for the purpose of PTFE placement in the present study are different from those for placement of an Angelchik prosthesis, so comparison of these two techniques is difficult. Migration of the PTFE is unlikely since it is stapled to the diaphragm. We do not as yet have long-term follow-up.

Edelman [4] has reported a series of 5 patients with paraesophageal hernia who were treated with laparoscopic hiatal herniorrhaphy with polypropylene mesh, gastropexy, and gastrostomy. Pitcher et al. [9] has reported a series of 12 patients with paraesophageal hernia who underwent laparoscopic repair; two of these required polypropylene mesh to close a large hiatus. Since polypropylene mesh has been associated with enterocutaneous fistula secondary to the polypropylene eroding into the bowel lumen [8], we employed PTFE for the onlay because there have been no reports of bowel erosion secondary to PTFE.

Determination of the efficacy and safety of PTFE reinforcement of posterior cruroplasty for the large hiatal defect will require 50–75 patients observed over 10–15 years. The short-term result in our first three patients has been satisfactory. We do not, however, recommend routine use of PTFE in hiatal herniorrhaphy. At the present we are placing

PTFE in patients with a large hernia sac and whose hiatal diameter is 8 cm or greater. The diameter indication was arrived at empirically; we do not have data specifying the hiatal diameter at which the risk for cruroplasty disruption is increased. We feel that the PTFE onlay provides a buttress where tissue is healing under tension and is subjected to stress from coughing, straining, retching, or obesity. We propose the use of PTFE when confronted with a large defect of the hiatus.

## References

1. Angelchik JP, Cohen R (1979) A new surgical procedure for the treatment of gastroesophageal reflux and hiatal hernia. *Surg Gynecol Obstet* 148: 246–248
2. Crookes PF, DeMeester TR (1994) The Angelchik prosthesis: what have we learned in fifteen years? *Ann Thorac Surg* 57: 1385–1386
3. Cuschieri A, Shimi S, Nathanson LK (1992) Laparoscopic reduction, crural repair, and fundoplication of large hiatal hernia. *Am J Surg* 163: 425–430
4. Edelman DS (1995) Laparoscopic paraesophageal hernia repair with mesh. *Surg Laparosc Endosc* 5: 32–37
5. Frantzides CT, Carlson MA (1995) Laparoscopic versus conventional fundoplication. *J Laparoendosc Surg* 5: 137–143
6. Hinder RA, Filipi CJ, Wetscher G, Neary P, DeMeester TR, Perdakis G (1994) Laparoscopic Nissen fundoplication is an effective treatment for gastroesophageal reflux disease. *Ann Surg* 220: 472–483
7. Jamieson GG, Watson DI, Britten-Jones R, Mitchell PC, Anvari M (1994) Laparoscopic Nissen fundoplication. *Ann Surg* 220: 137–145
8. Kaufman Z, Engelberg M, Zager M (1981) Fecal fistula: a late complication of Marlex mesh repair. *Dis Colon Rectum* 24: 543–544
9. Pitcher DE, Curet MJ, Martin DT, Vogt DM, Mason J, Zucker KA (1995) Successful laparoscopic repair of paraesophageal hernia. *Arch Surg* 130: 590–596
10. Rattner DW, Brooks DC (1995) Patient satisfaction following laparoscopic and open antireflux surgery. *Arch Surg* 130: 289–294
11. Stirling MC, Orringer MB (1986) Surgical treatment after the failed antireflux operation. *J Thorac Cardiovasc Surg* 92: 667–672
12. Wichterman K, Geha AS, Cahow CE, Baue AE (1979) Giant paraesophageal hiatus hernia with intrathoracic stomach and colon: the case for early repair. *Surgery* 86: 497–506