

27 Mesh-Reinforced Repair of Diaphragmatic Hernia

M.A. CARLSON, C.T. FRANTZIDES

Introduction

Simple closure of acquired diaphragmatic hernia has been accompanied by a high recurrence rate. In order to address this problem, we have been interested in reinforcing diaphragmatic hernia repair with prosthetic mesh. Our experience with this involves two clinical series, one a retrospective review of open polypropylene-reinforced hiatal herniorrhaphy and the other a randomized controlled trial of laparoscopic hiatal herniorrhaphy with and without polytetrafluoroethylene reinforcement. Our recurrence rate with mesh reinforcement of diaphragmatic hernia has been virtually nil. Here, we review diaphragmatic herniorrhaphy with mesh, describe our technique of laparoscopic hiatal herniorrhaphy with mesh reinforcement, and provide general recommendations for management of diaphragmatic hernia.

Definitions: Diaphragmatic Hernia

The discussion will be limited to acquired hernia of the diaphragm in the adult, which in the vast majority of cases will mean hernia through the esophageal hiatus, including paraesophageal hernia. Generally speaking, there are four types of hiatal hernia [1]: type I, or simple sliding hiatal hernia (the most common type by far, accounting for ~90% of hernias of the esophageal hiatus); type II, or true paraesophageal hernia (relatively rare; a partial herniation of the stomach with retention of the gastroesophageal junction below the diaphragm); type III, or mixed paraesophageal hernia (the most common paraesophageal hernia; a partial herniation of the stomach with displacement of the gastroesophageal junction above the diaphragm); and type IV, or massive paraesophageal hernia (herniation of the stomach and another intraabdominal organ into the chest). The anatomy of the hiatus as viewed from the abdomen is shown in Fig. 1. In the majority of subjects the esophageal hiatus is formed by a split in the right diaphragmatic crus [2]; the usual boundaries of the hiatus, therefore, are the right and left bundles of the right diaphragmatic crus. The right and left bundles typically are the two structures a surgeon approximates when performing sutured cruroplasty for hiatus hernia, e.g., during a Nissen fundoplication or a paraesophageal hernia repair. Since the vast majority of diaphragmatic hernias are through the esophageal hiatus, a primary (or traditional) repair as discussed in this review consists of a simple (sutured) cruroplasty.

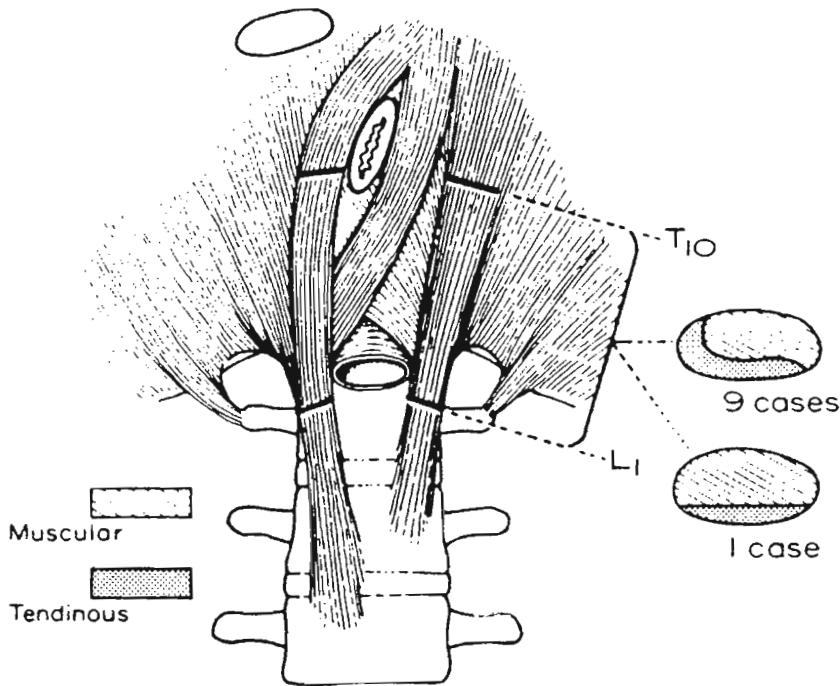


Fig. 1. Anatomy of the esophageal hiatus of the diaphragm as viewed from the abdomen. This configuration is present in ~50% of subjects. (Gray SW, Rowe JS, Jr., Skandalakis JE 1979. Surgical anatomy of the gastroesophageal junction. *Am Surg* 45: 575-87. Reprinted with permission)

Etiology and Pathophysiology of Diaphragmatic Hernia

Notwithstanding trauma, the etiology of acquired diaphragmatic hernia is largely unknown. Some underlying risk factors include obesity, pulmonary disease, gastroesophageal reflux disease, age, or congenital anomaly of the crura [1, 3]; these are conditions that weaken the crura and/or increase intraabdominal pressure. The hiatus is particularly prone to develop herniation, not only because of the prevalence of the above risk factors, but also because of the approximately 14 000 cycles of respiration the diaphragm undergoes every day (not including coughing, straining, sneezing etc.). This frequent and obligatory muscular contraction also makes any surgical repair prone to breakdown. These circumstances contribute to the relatively high recurrence rate of diaphragmatic hernia repair (see below), which has been our impetus for employment of mesh reinforcement.

Recurrence After Traditional Diaphragmatic Hernia Repair

Early experience with primary diaphragmatic hernia repair, which consists of various techniques of sutured cruroplasty, demonstrated a recurrence rate that

ten patients with a hiatal defect >5 cm. All of these reports represent small retrospective series (= 10 patients); with the exception of our randomized trial described below, there has been no prospective evaluation of mesh in the repair of diaphragmatic hernia.

Mesh-Reinforced Open Diaphragmatic Hernia Repair: Our Retrospective Series [11]

The problem of recurrence after simple cruroplasty for a large hiatal hernia (especially paraesophageal hernia with an intrathoracic stomach) was addressed at the Medical College of Wisconsin (Milwaukee) in the 1970s, when a policy of polypropylene-reinforced paraesophageal hernia repair was instituted. The procedure (open transabdominal approach) consisted of a sutured posterior cruroplasty onto which a polypropylene (Marlex) onlay (with a »keyhole« to accommodate the esophagus) was placed, followed by a gastrostomy. Over a 15-year period, 44 patients with intrathoracic stomach were treated in such a manner [11]. After a mean follow-up period of 52 months (range 2 months to 15 years), the clinical recurrence rate was zero. There was one patient in which the mesh eroded into the esophagus at a site which had been biopsied repeatedly (the patient had Barrett's with dysplasia). The erosion was asymptomatic, but the patient ultimately required esophagectomy for adenocarcinoma. The pathologic specimen confirmed the cancer, but not present at the erosion (this site contained a benign ulcer). There were no other mesh-related complications or long-term side effects. A good-to-excellent long-term result (Visick I-II) [12] was obtained in 38 of 43 patients (88%) available for follow up. This collection of cases remains the largest published retrospective series of prosthesis-reinforced diaphragmatic hernia repairs, either open or laparoscopic.

Mesh-Reinforced Minimally Invasive Diaphragmatic Hernia Repair: Our Randomized Trial [13]

Encouraged by our result with open diaphragmatic repair with mesh, we elected to perform such repairs laparoscopically. One theoretical concern we had in using mesh (especially polypropylene) at the hiatus, however, was erosion into a hollow viscera, which happened in one patient from our open series (see above). Polypropylene mesh erosion into exposed bowel has been an occasional problem in the repair of defects of the anterior abdominal wall, especially with defects involving acute inflammation and/or infection [14]. We believed that the use of PTFE at the hiatus might lessen the risk for erosive complications, since it was difficult to find published evidence of a bowel fistula with PTFE mesh as the primary cause. The other theoretical concern we had was whether mesh actually was indicated in the repair of diaphragmatic hernia. Our retrospective series suggested that utilization of mesh was beneficial, but we did not have any controlled data. Therefore, after a small number of cases to demonstrate the feasibility of minimally invasive hiatal herniorrhaphy with PTFE onlay reinforcement [15], we embarked on a ran-

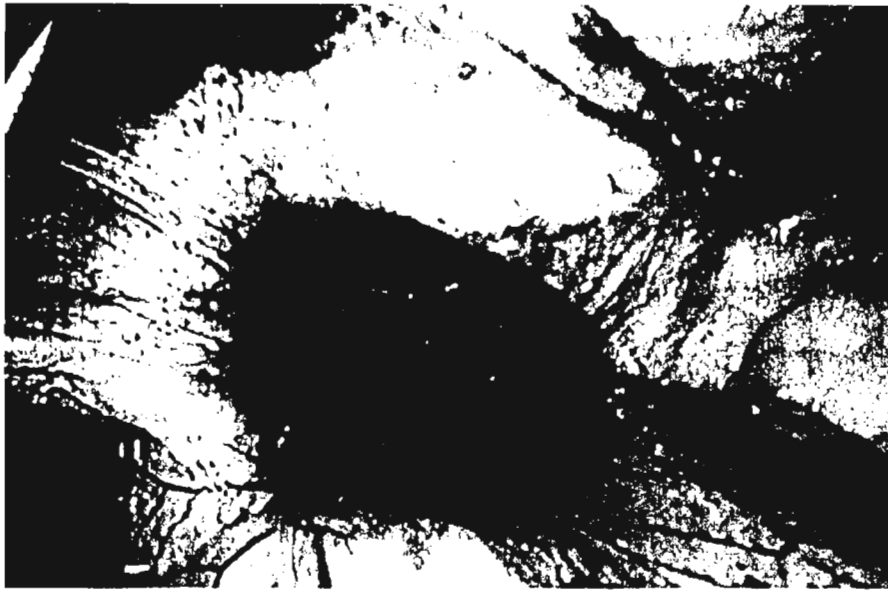


Fig. 2. Typical hiatal defect present in a patient enrolled into the randomized trial of PTFE reinforcement of posterior cruroplasty during minimally invasive Nissen fundoplication [13].

domized controlled trial to test whether mesh placement reduced the recurrence rate after laparoscopic diaphragmatic hernia repair.

We argued that any theoretical benefit of mesh placement most likely would exist in the patient who had a large hiatal defect (which we defined as ≥ 8 cm). Seventy-two patients with gastroesophageal reflux disease and large defect (≥ 8 cm) hiatal hernia (Fig. 2) were enrolled into this study [13]. The study population consisted of a subset of all patients (> 600) undergoing a primary minimally invasive antireflux procedure by the senior author (CTF). The decision whether to enroll a patient into the study was made after intraoperative measurement of the hiatal defect. A subject then was randomized, and a simple posterior cruroplasty with or without PTFE onlay reinforcement (see subsequent section on technique) followed by a floppy Nissen fundoplication was performed. The recurrence rate in the cruroplasty only group was 22% (8 of 36); the rate in the cruroplasty plus PTFE group was zero (mean follow-up period = 3.3 years). There were no mesh-related complications. We concluded that PTFE reinforcement of posterior cruroplasty was indicated for hiatal defects ≥ 8 cm.

Mesh-Reinforced Minimally Invasive Diaphragmatic Hernia Repair: Technique

Our technique of minimally invasive diaphragmatic hernia repair has been described in detail elsewhere [1]. The patient is placed in a modified lithotomy position with 15–20° of reverse-Trendelenburg tilt, and the surgeon stands between the

Carlson: There are many more esophageal erosions than published in the literature. So it's difficult to give a definite answer, but there seem to be more problems with the polypropylene and I would not use polypropylene at the hiatus. So far it seems that ePTFE is OK. Currently, we use a dual mesh.

Franklin: I use Gore-Tex mesh and I never saw an erosion into the esophagus; but what happens with the dual mesh after the reconstruction? How many of your patients are suffering from dysphagia due to mesh shrinkage?

Carlson: I know that there are reports of using a u-shaped dual mesh. I don't know whether this might withhold postoperative dysphagia. We use a 60 French bougie during the mesh placement and normally we don't have problems with dysphagia; but I cannot really comment on this.

LeBlanc: In experimental animal studies the dual mesh showed a shrinkage of about 50%. So this will severely compromise the lumen and it has not been studied in hiatal repair anywhere.

DeBord: In your study you compared hiatal suture versus circumferential mesh. Did you think that pieces of mesh put under the sutures in order to protect the suture from tearing out might be helpful?

Carlson: Might be so.