

Case Report

Laparoscopic Repair of Incarcerated Diaphragmatic Hernia with Mesh

CONSTANTINE T. FRANTZIDES, MD, PhD, FACS,¹ ATUL K. MADAN, MD, FACS,²
JOHN ZOGRAFAKIS, MD,³ and CLAIRE SMITH, MD, FACR⁴

ABSTRACT

Diaphragmatic hernias are now being approached laparoscopically. Incarcerated diaphragmatic hernia poses a special problem due to concerns about contamination. We describe a laparoscopic repair of such a hernia with the use of prosthetic mesh.

INTRODUCTION

LAPAROSCOPY HAS CHALLENGED THE TRADITIONAL approaches to many surgical issues. One such issue, diaphragmatic hernia, has been previously addressed with a thoracotomy or laparotomy. Laparoscopy has now been utilized for the repair of diaphragmatic ruptures and hernia.¹⁻¹² Our previous experience includes the use of mesh reinforcement for large, chronic diaphragmatic, and/or hiatal hernias.^{13,14} While mesh has been placed in contaminated cases, it has not been described for repairs of the diaphragm during contaminated procedures.¹⁵ We believe this is the first reported case of laparoscopic repair of a chronic traumatic diaphragmatic hernia with the use of mesh during a clean-contaminated case and we discuss the various options in minimally invasive repair of diaphragmatic defects.

CASE REPORT

A 73-year-old man with a 1-year history of constipation and intermittent pain with bowel movements was ad-

mitted to the hospital to be evaluated for a large bowel obstruction. He only had a vague history of a motor vehicle collision when he was a young adult. A colonoscopy and a barium enema were performed. These tests revealed herniation of the splenic flexure of the colon through the diaphragm (Fig. 1).

The abdomen was soft, nontender, and nondistended with normal, active bowel sounds. Rectal examination revealed no masses or gross bleeding. The patient was taken to the operating room for a laparoscopic repair of a diaphragmatic hernia after a mechanical bowel preparation as well as oral neomycin and erythromycin. Intravenous antibiotics were given preoperatively.

The patient was placed in the lithotomy position and five trocars (10/11 mm) were placed (Fig. 2). The omentum and the colon were found to be stuck in a left anterolateral diaphragmatic hernia that measured about 6 × 12 cm (Fig. 3). A combination of blunt and sharp dissection was used to reduce the omentum and the colon into the abdomen. Upon reduction, an ischemic portion of the colon and a colotomy were noted. The the ischemic area was approximately 2 cm and the colotomy measured approximately 0.5 cm. The colotomy appeared to occur

¹Department of Surgery, Northwestern University, Evanston, Illinois.

²Department of Surgery, University of Tennessee, Memphis, Tennessee.

³Department of Surgery, Summa Health System, Akron, Ohio.

⁴Department of Diagnostic Radiology and Nuclear Medicine, Rush University, Chicago, Illinois.

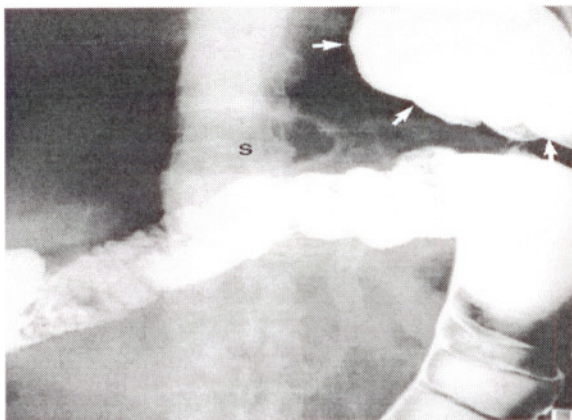


FIG. 1. Overhead radiograph of the left midabdomen from a barium enema study. Small arrows outline the splenic flexure area of the colon herniating through the left hemidiaphragm. The gas filled stomach (S) is in the normal subdiaphragmatic location.

during reduction, although the ischemic area was due to strangulation from the hernia. No enteric spillage was noted. This area was oversewn with interrupted silk sutures in two layers. The rest of the colon looked viable.

Endostitch sutures (Surgidac, United States Surgical, Norwalk, CT) were initially used to close the defect in the diaphragm (Fig. 4). Before placing our last suture, increased tidal volume was given by anesthesia to decrease any residual pneumothorax. Sepramesh (Genzyme Surgical Products, Cambridge, MA) was utilized to reinforce the repair. A hernia stapler (Ethicon Endo-Surgery, Cincinnati, OH) was used to fix the mesh over the repair (Fig. 5). All port sites were closed. The patient was transferred to the recovery room extubated.

On postoperative day 2, the patient was noted to have some urinary retention. After this resolved, the patient was discharged on postoperative day 4 with 10 days of oral antibiotics. He was doing well 24 months after surgery without evidence of radiological recurrence or infection.

DISCUSSION

Before the widespread adoption of laparoscopy, the approach to chronic traumatic diaphragmatic hernia included a thoracotomy, reduction of intra-abdominal contents, and closure of the diaphragmatic defect; the approach to acute traumatic diaphragmatic hernia included a laparotomy, reduction of intra-abdominal contents, and closure of the diaphragmatic defect. As early as 1976, thoracoscopy was utilized in the evaluation of diaphragmatic injuries.¹⁶ In 1984, a case series described the use of laparoscopy with suspected diaphragmatic in-

jury.¹ Other trauma centers demonstrated the use of laparoscopy for trauma.¹⁷

Thoracoscopic evaluation of the diaphragm is possible.¹⁸ Laparoscopic evaluation is our choice; however, it may be limited in the evaluation of right sided posterior defects.¹⁹ Some have suggested the use of laparoscopy for left sided injuries but have recommended thoracoscopy for right sided injuries.^{4,20} In addition to evaluation, the repair of acute diaphragmatic injuries can be accomplished via laparoscopy. Frantzides and Carlson described the first laparoscopic closure of a penetrating injury to the diaphragm in 1994.² The repair was accomplished with a hernia stapler. Other techniques such as laparoscopic suturing have also been described.^{3,5}

While late diaphragmatic hernias have traditionally been approached from the chest, the laparoscopic approach may be used for late or chronic diaphragmatic hernias.⁶⁻¹² We have previously described the repair of a recurrent chronic diaphragmatic hernia.¹⁴ These large defects often cannot be closed with simple suture closure. Most surgeons report the need of mesh repair for large traumatic diaphragmatic defects.^{8,10-12} The continual stress of the diaphragm from respiratory movement, cardiac motion, and other motions during Valsalva, coughs, sighs, exercise, and change in position is a reason to consider mesh reinforcement during any type of large diaphragmatic repair. We extrapolated the need for mesh from our experience with large hiatal hernias.¹³ For chronic diaphragmatic hernias, the tension on the primary repair is usually great enough to justify mesh reinforcement. This was the case in our patient. In light of the possibility of contamination, the decision to place mesh should be considered with caution. Our usual choice of

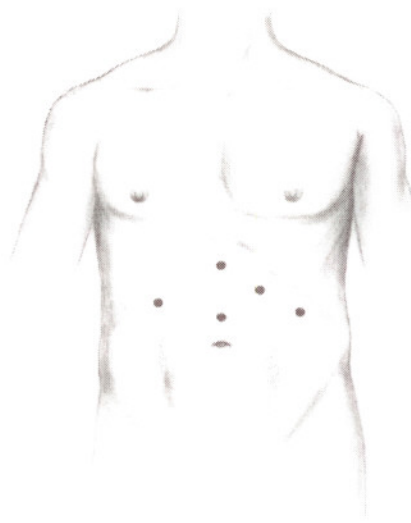


FIG. 2. Schematic diagram of port placement.

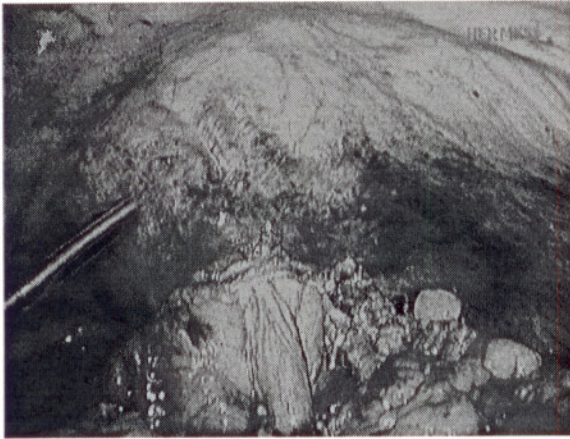

FIG. 3. Intraoperative photograph shows the omentum and colon incarcerated through the diaphragmatic defect.

mesh is polytetrafluoroethylene (PTFE), which has been used for large hiatal hernias and other longstanding diaphragmatic defects.^{13,14,21-23} Our group published a randomized study of patients with large hiatal hernias, demonstrating that PTFE mesh reinforcement reduces the recurrence rate.¹³ Other meshes are available as well. The use of polypropylene mesh has been reported to have the benefits of excellent tissue ingrowth and strong suture line.¹¹ We consider that the decreased tendency of PTFE to form adhesions makes it more desirable. In addition, erosion of polypropylene mesh into the gastrointestinal tract is a major concern,^{24,25} while the placement of polypropylene mesh may cause thick fibrous adhesions which may make future abdominal approaches more difficult.




FIG. 4. Intraoperative photograph demonstrates the defect which has been partially repaired with interrupted sutures.

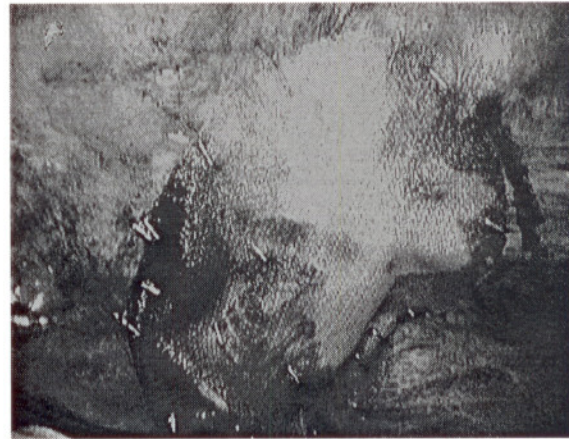


FIG. 5. Intraoperative photograph shows the repair suture reinforced with mesh.

However, placement of PTFE in an infected field is not advisable. We feel polypropylene is a much better mesh material to be placed in a clean-contaminated field even if the patient had bowel preparation. While we gave this patient oral antibiotics for an extended period (2 weeks), we have no data to justify this practice. While diaphragmatic hernias present no specific difficulties during clean-contaminated cases, we were concerned about foreign body infection in this specific case. Thus, we used Sepramesh, which is a polypropylene mesh knitted from 6-mil monofilament fibers that is coated on one side with chemically modified sodium hyaluronate/carboxymethyl cellulose. It has been shown to have reduced adhesion formation in multiple animal studies.²⁶⁻²⁸ A variety of biologic meshes are now available and offer alternates for prosthetic material in clean-contaminated areas.

We fixed the mesh to the diaphragm with an endoscopic hernia stapler in our case. Suturing the mesh to the diaphragm is possible; however, the hernia stapler permits securing the mesh easily and efficiently, especially when the angles are awkward. A laparoscopic tacker may be helpful to fix the mesh. Unfortunately, most tackers require a large amount of inward pressure. This pressure may be very dangerous near the pericardium since the pressure can inadvertently place the tack in the heart. For this reason, we used a laparoscopic hernia stapler. Care must still be taken when firing the laparoscopic hernia stapler close to the pericardium where the diaphragm is relatively thinner. An advantage of the stapler is that it can be fired slowly so that each leg of the staple is partially exposed. One leg can be used to carefully grab the diaphragm and the other to anchor the mesh. Continued firing of the stapler will form the staple without the need for dangerous inward pressure.

CONCLUSION

We report a first case of laparoscopic repair of chronic traumatic diaphragmatic hernia with the use of mesh during a clean-contaminated case. The laparoscopic repair of chronic diaphragmatic hernia is an excellent option that should be at least considered for all diaphragmatic defects.

ACKNOWLEDGMENT

The authors would like to acknowledge the technical assistance of Courtney Bishop in the preparation of this manuscript.

REFERENCES

- Adamthwaite DN. Traumatic diaphragmatic hernia: a new indication for laparoscopy. *Br J Surg* 1984;71:315.
- Frantzides CT, Carlson MA. Laparoscopic repair of a penetrating injury to the diaphragm: a case report. *J Laparoendosc Surg* 1994;4:153-156.
- Marks JM, Ramey RL, Baringer DC, et al. Laparoscopic repair of diaphragmatic laceration. *Surg Laparosc Endosc* 1995;5:415-418.
- Lindsey I, Woods SDS, Nottle PD. Laparoscopic management of blunt diaphragmatic injury. *Aust N Z J Surg* 1997;67:619-621.
- Smith CH, Novick TL, Jacobs DG, et al. Laparoscopic repair of a ruptured diaphragm secondary to blunt trauma. *Surg Endosc* 2000;14:501-502.
- Meyer G, Huttel TP, Hatz RA, et al. Laparoscopic repair of traumatic diaphragmatic hernias. *Surg Endosc* 2000;14:1010-1014.
- Domene CE, Volpe P, Santo MA, et al. Laparoscopic treatment of traumatic diaphragmatic hernia. *J Laparoendosc Adv Surg Techn* 1998;8:225-229.
- Pross M, Manger T, Mirow L, et al. Laparoscopic management of late-diagnosed major diaphragmatic rupture. *J Laparoendosc Adv Surg Techn* 2000;10:111-114.
- Matz A, Aliz M, Charuzi I, et al. The role of laparoscopy in the diagnosis and treatment of missed diaphragmatic rupture. *Surg Endosc* 2000;14:537-539.
- Shah S, Matthews BD, Sing RF, et al. Laparoscopic repair of a chronic diaphragmatic hernia. *Surg Laparosc Endosc Percutan Techn* 2000;10:182-186.
- Slim K, Bousquet J, Chipponi J. Laparoscopic repair of missed blunt diaphragmatic rupture using a prosthesis. *Surg Endosc* 1998;12:1358-1360.
- Campos LI, Sipes EK. Laparoscopic repair of diaphragmatic hernia. *J Laparoendosc Surg* 1991;1:369-373.
- Frantzides CT, Madan AK, Carlson MA, et al. A prospective, randomized trial of laparoscopic polytetrafluoroethylene (PTFE) patch repair versus simple cruroplasty for large hiatal hernia. *Arch Surg* 2002;137:649-652.
- Frantzides CT, Madan AK, O'Leary PJ, et al. Laparoscopic repair of recurrent chronic traumatic diaphragmatic hernia. *Am Surg* 2003;69:160-162.
- Kelly ME, Behrman SW. The safety and efficacy of prosthetic hernia repair in clean-contaminated and contaminated wounds. *Am Surg* 2002;68:524-529.
- Jackson AM, Ferreira AA. Thoracoscopy as an aid to the diagnosis of diaphragmatic injury in penetrating wounds of the left lower chest: a preliminary report. *Injury* 1976;7:213-217.
- Fabian TC, Croce MA, Stewart RM, et al. A prospective analysis of diagnostic laparoscopy in trauma. *Ann Surg* 1993;217:557-564.
- Sukul DM, Kates E, Jahannes EJ. Sixty three cases of traumatic injury of the diaphragm. *Injury* 1991;22:303-306.
- Feliciano DV, Cruse PA, Mattox KL, et al. Delayed diagnosis of injuries to the diaphragm after penetrating wounds. *J Trauma* 1988;28:1135-1144.
- Martin I, O'Rourke N, Gotley D, et al. Laparoscopy in the management of diaphragmatic rupture due to blunt trauma. *Aust N Z J Surg* 1998;68:584-586.
- Frantzides CT, Carlson MA. Prosthetic reinforcement of posterior cruroplasty during laparoscopic hiatal herniorrhaphy. *Surg Endosc* 1997;11:769-771.
- Frantzides CT, Carlson MA, Pappas C, et al. Laparoscopic repair of a congenital diaphragmatic hernia in an adult. *J Laparoendosc Adv Surg Techn* 2000;10:287-290.
- Frantzides CT, Richards CG, Carlson MA. Laparoscopic repair of large hiatal hernia with polytetrafluoroethylene. *Surg Endosc* 1999;13:906-908.
- Carlson MA, Condon RE, Ludwig KA, et al. Management of intrathoracic stomach with polypropylene mesh prosthesis reinforced transabdominal hiatus hernia repair. *J Am Coll Surg* 1998;187:227-230.
- Schneider R, LHerrington J, Granda AM. Marlex mesh in repair of a diaphragmatic repair later eroding into the distal esophagus and stomach. *Am Surg* 1979;45:337-339.
- Alponat A, Lakshminarasappa SR, Yavuz N, et al. Prevention of adhesions by Sefrafilm, an absorbable adhesion barrier: an incisional hernia model in rats. *Am Surg* 1997;63:818-819.
- Dinsmore RC, Calton WC. Prevention of adhesions to polypropylene mesh in a rabbit model. *Am Surg* 1999;65:383-387.
- Greenawalt KE, Butler TJ, Rowe EA, et al. Evaluation of sepramesh biosurgical composite in a rabbit hernia repair model. *J Surg Res* 2000;94:92-98.

Address reprint requests to:
 Constantine T. Frantzides, MD, PhD, FACS
 Chicago Institute of Minimally Invasive Surgery
 Northwestern University
 64 Old Orchard Center, Suite 409
 Skokie, IL 60077

E-mail: cfrantzides@enh.org

CONCLUSION

We report a first case of laparoscopic repair of chronic traumatic diaphragmatic hernia with the use of mesh during a clean-contaminated case. The laparoscopic repair of chronic diaphragmatic hernia is an excellent option that should be at least considered for all diaphragmatic defects.

ACKNOWLEDGMENT

The authors would like to acknowledge the technical assistance of Courtney Bishop in the preparation of this manuscript.

REFERENCES

1. Adamthwaite DN. Traumatic diaphragmatic hernia: a new indication for laparoscopy. *Br J Surg* 1984;71:315.
2. Frantzides CT, Carlson MA. Laparoscopic repair of a penetrating injury to the diaphragm: a case report. *J Laparoendosc Surg* 1994;4:153-156.
3. Marks JM, Ramey RL, Baringer DC, et al. Laparoscopic repair of diaphragmatic laceration. *Surg Laparosc Endosc* 1995;5:415-418.
4. Lindsey I, Woods SDS, Nottle PD. Laparoscopic management of blunt diaphragmatic injury. *Aust N Z J Surg* 1997;67:619-621.
5. Smith CH, Novick TL, Jacobs DG, et al. Laparoscopic repair of a ruptured diaphragm secondary to blunt trauma. *Surg Endosc* 2000;14:501-502.
6. Meyer G, Huttel TP, Hatz RA, et al. Laparoscopic repair of traumatic diaphragmatic hernias. *Surg Endosc* 2000;14:1010-1014.
7. Domene CE, Volpe P, Santo MA, et al. Laparoscopic treatment of traumatic diaphragmatic hernia. *J Laparoendosc Adv Surg Techn* 1998;8:225-229.
8. Pross M, Manger T, Mirow L, et al. Laparoscopic management of late-diagnosed major diaphragmatic rupture. *J Laparoendosc Adv Surg Techn* 2000;10:111-114.
9. Matz A, Aliz M, Charuzi I, et al. The role of laparoscopy in the diagnosis and treatment of missed diaphragmatic rupture. *Surg Endosc* 2000;14:537-539.
10. Shah S, Matthews BD, Sing RF, et al. Laparoscopic repair of a chronic diaphragmatic hernia. *Surg Laparosc Endosc Percutan Techn* 2000;10:182-186.
11. Slim K, Bousquet J, Chipponi J. Laparoscopic repair of missed blunt diaphragmatic rupture using a prosthesis. *Surg Endosc* 1998;12:1358-1360.
12. Campos LI, Sipes EK. Laparoscopic repair of diaphragmatic hernia. *J Laparoendosc Surg* 1991;1:369-373.
13. Frantzides CT, Madan AK, Carlson MA, et al. A prospective, randomized trial of laparoscopic polytetrafluoroethylene (PTFE) patch repair versus simple cruroplasty for large hiatal hernia. *Arch Surg* 2002;137:649-652.
14. Frantzides CT, Madan AK, O'Leary PJ, et al. Laparoscopic repair of recurrent chronic traumatic diaphragmatic hernia. *Am Surg* 2003;69:160-162.
15. Kelly ME, Behrman SW. The safety and efficacy of prosthetic hernia repair in clean-contaminated and contaminated wounds. *Am Surg* 2002;68:524-529.
16. Jackson AM, Ferreira AA. Thoracoscopy as an aid to the diagnosis of diaphragmatic injury in penetrating wounds of the left lower chest: a preliminary report. *Injury* 1976;7:213-217.
17. Fabian TC, Croce MA, Stewart RM, et al. A prospective analysis of diagnostic laparoscopy in trauma. *Ann Surg* 1993;217:557-564.
18. Sukul DM, Kates E, Jahannes EJ. Sixty three cases of traumatic injury of the diaphragm. *Injury* 1991;22:303-306.
19. Feliciano DV, Cruse PA, Mattox KL, et al. Delayed diagnosis of injuries to the diaphragm after penetrating wounds. *J Trauma* 1988;28:1135-1144.
20. Martin I, O'Rourke N, Gotley D, et al. Laparoscopy in the management of diaphragmatic rupture due to blunt trauma. *Aust N Z J Surg* 1998;68:584-586.
21. Frantzides CT, Carlson MA. Prosthetic reinforcement of posterior cruroplasty during laparoscopic hiatal herniorrhaphy. *Surg Endosc* 1997;11:769-771.
22. Frantzides CT, Carlson MA, Pappas C, et al. Laparoscopic repair of a congenital diaphragmatic hernia in an adult. *J Laparoendosc Adv Surg Techn* 2000;10:287-290.
23. Frantzides CT, Richards CG, Carlson MA. Laparoscopic repair of large hiatal hernia with polytetrafluoroethylene. *Surg Endosc* 1999;13:906-908.
24. Carlson MA, Condon RE, Ludwig KA, et al. Management of intrathoracic stomach with polypropylene mesh prosthesis reinforced transabdominal hiatus hernia repair. *J Am Coll Surg* 1998;187:227-230.
25. Schneider R, LHerrington J, Granda AM. Marlex mesh in repair of a diaphragmatic repair later eroding into the distal esophagus and stomach. *Am Surg* 1979;45:337-339.
26. Alponat A, Lakshminarasappa SR, Yavuz N, et al. Prevention of adhesions by Seprafilm, an absorbable adhesion barrier: an incisional hernia model in rats. *Am Surg* 1997;63:818-819.
27. Dinsmore RC, Calton WC. Prevention of adhesions to polypropylene mesh in a rabbit model. *Am Surg* 1999;65:383-387.
28. Greenawalt KE, Butler TJ, Rowe EA, et al. Evaluation of sepramesh biosurgical composite in a rabbit hernia repair model. *J Surg Res* 2000;94:92-98.

Address reprint requests to:

Constantine T. Frantzides, MD, PhD, FACS
Chicago Institute of Minimally Invasive Surgery
Northwestern University
64 Old Orchard Center, Suite 409
Skokie, IL 60077

E-mail: cfrantzides@enh.org