

Minimally Invasive Ventral Herniorrhaphy

CONSTANTINE T. FRANTZIDES, M.D., Ph.D., FACS, and MARK A. CARLSON, M.D.

ABSTRACT

Three types of minimally invasive ventral herniorrhaphies were performed in eight patients: primary repair with sutures (1 case), single-layer prosthesis repair with polytetrafluoroethylene (4 cases), and bilayer prosthesis repair with polytetrafluoroethylene and polypropylene (3 cases). One patient undergoing the bilayer repair developed a small hematoma in the subcutaneous tissue at the site of the repair, which resolved without intervention. There were no other complications, and no recurrence was noted in follow-up of 14 to 20 months.

INTRODUCTION

Open repair of an abdominal wall defect with a prosthetic such as polypropylene (PPE) or polytetrafluoroethylene (PTFE) is an accepted technique.^{1,2} This technique is now being applied laparoscopically.³⁻⁶ The minimally invasive ventral hernia repair is not standardized; here, we present our various approaches created for different clinical situations.

MATERIALS AND METHODS

Laparoscopic ventral hernia repairs were performed in eight patients. Three different types of repairs were utilized (Table 1). All patients received 2 g of Cefazolin sodium with induction of anesthesia.

Primary repair with sutures

An umbilical hernia was found in a patient being evaluated for a laparoscopic Nissen fundoplication. The defect was nearly 2 cm in diameter and had a small sac without incarceration. At operation, all trocars were placed in their normal locations (that is, well above the umbilicus) to perform a fundoplication. After the wrap was completed, the laparoscope was transferred from the midline port to a right upper quadrant port, and the defect was visualized. A 30-degree viewing scope facilitated visualization of the defect. Adherent omentum was taken down from the hernia sac. The edges of the defect were approximated with three interrupted sutures of 2-0 polyester using the Endostitch (US Surgical, Norwalk, CT). All trocar sites were closed with a fascial closer.

Minimally Invasive Surgery Center, Department of Surgery, Medical College of Wisconsin, Milwaukee, Wisconsin.

FRANTZIDES AND CARLSON

TABLE 1. LAPAROSCOPIC VENTRAL HERNIAS

<i>Number of patients</i>	<i>Location and size of hernia (CM)</i>	<i>Type of repair</i>
1	Umbilical hernia (2 cm)	Primary repair with sutures
4	Ventral hernia (3–4 cm)	Single-layer prosthesis (PTFE)
3	Ventral hernia (5–8 cm)	Bilayer PTFE/PPE prosthesis

Single-layer prosthesis

Four patients with a small (3–4-cm in diameter) midline incisional hernia underwent laparoscopic incisional herniorrhaphy with a single layer of PTFE (W.L. Gore and Associates, Inc., Flagstaff, AZ). Three 10-to 11-mm trocars were placed in the lateral abdomen (all on one side) as far away from the defect as possible, well spaced from each other. Rotating the patient toward the nonoperative side displaced the bowel from the region of the trocar placement. Having all ports on one side allowed the surgeon to operate with two hands with a normal (nonmirror image) view of the operative field on the monitor. If necessary, a fourth trocar may be placed in the contralateral abdomen, but the assistant operating through this port will have a mirror image view. As noted above, a 30-degree scope allowed an upward view of the anterior abdominal wall. Adhesions to the hernia sac were lysed. The edges of the defect were confirmed both by internal inspection and by external palpation. PTFE mesh was inserted through a trocar into the abdomen. Using two graspers, the mesh was positioned intraperitoneally to cover the defect. While an assistant used one grasper to hold the mesh, the surgeon fired a hernia stapler (Ethicon Endo-Surgery, Cincinnati, OH) around the perimeter of the mesh. The surgeon's second hand provided abdominal wall pressure against the stapler to ensure anchoring of the staples. External pressure also brings the operative field down into view of the camera. Staples were placed into the center of the mesh to obliterate the potential space of the sac. Trocar sites were closed using a fascial closer.

Bilayer prosthesis

Three patients with a larger incisional hernia (5–8-cm in diameter) underwent laparoscopic incisional herniorrhaphy with a bilayer prosthetic composed of one layer each of PTFE and PPE. Trocar placement was similar to that of the single-layer PTFE hernia repair. The diameter of the defect was measured with a calibrated blunt probe. A piece of PPE mesh was cut on the back table with a diameter of at least 2 cm greater than the hernia defect. The PPE was sewn to the uncut PTFE mesh with a nonabsorbable suture in a continuous, circumferential fashion, taking care that the PTFE completely overlapped the PPE (Fig. 1). This bilayer mesh was tightly rolled and inserted into the abdomen through a trocar. The prosthetic was then stapled in place (intraperitoneally) as described above, with the PPE facing the abdominal wall and the PTFE facing the intra-abdominal contents (Fig. 2).

RESULTS

All patients were discharged from the hospital the first postoperative day. There were no recurrences at 14- and 20-month follow-ups. One of the three patients who underwent laparoscopic ventral herniorrhaphy with the bilayer technique was a morbidly obese woman with a midline hernia from a previous emergency Caesarian section. On the second postherniorrhaphy day, a firm, asymptomatic 3-cm mass was noted at the repair site. It was feared that a disruption of the repair had occurred. A computed tomography scan revealed, however, that the repair was intact and that the umbilical mass was probably a hematoma or seroma. It resolved spontaneously during follow-up, and at 14 months, the patient is doing well.

MINIMALLY INVASIVE VENTRAL HERNIORRHAPHY




FIG. 1. The bilayer prosthesis consists of one layer of PTFE and one layer of PPE mesh.

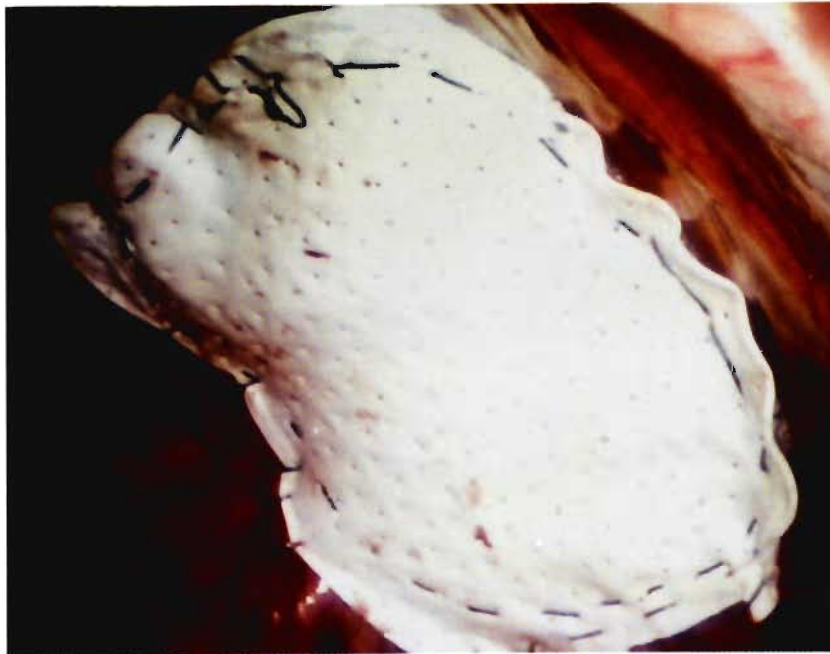


FIG. 2. The bilayer prosthesis is anchored in place with staples.

DISCUSSION

During the last 3 years, there have been a few reports on laparoscopic ventral hernia repairs, including incisional hernias.^{3,8} Three techniques of laparoscopic ventral herniorrhaphy are presented in this report: primary repair, single-layer prosthetic repair, and bilayer composite repair. For a small (<2 cm) defect found incidentally at laparoscopy, we presently are favoring primary repair if the hernia can be closed without undue tension. Currently, we are inclined to perform planned laparoscopic ventral herniorrhaphy for the moderate-sized (up to 8 cm) defect. For this, we favor a bilayer composite prosthesis of PTFE and PPE, which takes advantage of the tissue incorporation characteristic of PPE and the relative benign behavior of PTFE toward the viscera. Although the bilayer prosthesis is placed intra-abdominally, the PTFE layer completely covers the PPE, thus simulating the open bilayer, tension-free repair for large, incisional ventral hernias. We are hesitant to repair larger (>8 cm) hernias laparoscopically until we see some long-term follow-up in our (and other surgeons') patients who have had repair of a moderate-sized defect.

Although as yet unproven, the potential benefits of minimally invasive ventral herniorrhaphy with respect to open repair should include less postoperative pain, less dissection and tissue trauma, lower incidence of wound and prosthesis infection, improved cosmesis, and quicker recovery.

REFERENCES

1. Usher FC: The repair of incisional hernias. *Surg Gynecol Obstet* 1970;131:525-530.
2. Bauer JJ, Salky BA, Gelernt IM, Kreel I: Repair of large abdominal wall defects with expanded polytetrafluoroethylene (PTFE). *Ann Surg* 1987;206:765-769.
3. Felix EL, Michas C: Laparoscopic repair of Spigelian hernias. *Surg Laparosc Endosc* 1994;4:308-310.
4. LeBlanc KA, Booth WV: Laparoscopic repair of incisional abdominal hernias using expanded polytetrafluoroethylene: Preliminary findings. *Surg Laparosc Endosc* 1993;3:39-41.
5. Barie PS, Mack CA, Thompson WA: A technique for laparoscopic repair of herniation of the anterior abdominal wall using a composite mesh prosthesis. *Am J Surg* 1995;170:62-63.
6. Saiz AA, Willis IH, Paul DK, Sivina M: Laparoscopic ventral hernia repair: A community hospital experience. *Am Surg* 1996;62:336-338.
7. Carter JE, Miles C: Laparoscopic diagnosis and repair of spigelian hernia: Report of a case and technique. *Am J Obstet Gynecol* 1992;167:77-78.
8. Park A, Gagner M, Pomp A: Laparoscopic repair of large incisional hernias. *Surg Laparosc Endosc* 1996;6:123-128.

Address reprint requests to:
C.T. Frantzides, M.D., Ph.D.
Minimally Invasive Surgery Center
Medical College of Wisconsin
9200 West Wisconsin Avenue
Milwaukee, Wisconsin 53226