

## Brief Clinical Report

# Laparoscopic Closure of Gastric Stab Wounds: A Case Report

Constantine T. Frantzides, M.D., Ph.D., Kirk A. Ludwig, M.D.,  
Charles Aprahamian, M.D., and Basil Salaymeh, M.D.

---

**Summary:** For years laparoscopy has been used selectively in the diagnosis of blunt and penetrating injuries to the abdomen. Recent advances in instrumentation have taken laparoscopy beyond its limited role in diagnosis. Use of the laparoscope for therapeutic intervention in selected cases of abdominal trauma is now possible. Here we report the use of laparoscopic techniques to diagnose and treat two stab wounds to the anterior wall of the stomach. **Key Words:** Trauma—Laparoscopy—Stomach.

---

The management of penetrating abdominal trauma is in the process of evolution. Mandatory laparotomy following penetrating abdominal trauma has been replaced by selective intervention (1). Whereas most abdominal gunshot wounds are best treated by laparotomy, abdominal stab wounds in many instances call for selective management. The high incidence of nontherapeutic laparotomies and their associated morbidity in patients who have abdominal stab wounds but who are stable and without significant physical findings has led to this change in management (1,2).

Selective operation in patients with abdominal stab wounds has decreased the incidence of negative laparotomy dramatically (3-7). In an attempt to reduce this incidence further, use of laparoscopy has been proposed (8-11). Until recently laparoscopy has been considered only as a diagnostic modality. New instrumentation combined with a realization of the potentials for laparoscopic intervention will change this view.

### CASE REPORT

A 38-year-old man was brought to the trauma room by paramedics after he sustained two abdominal stab wounds. Injuries included a 1-cm stab wound in the left midaxillary line at the level of T10 and a 1-cm stab wound in the left midclavicular line just below the costal margin. Neither wound was actively bleeding. Physical examination revealed abdominal wall tenderness in the region of the wounds but no peritoneal signs. Hemodynamics were entirely stable. Laboratory studies showed a hematocrit of 41% and a white blood cell count of 5,900 cells/mm<sup>3</sup>. Chest and abdominal x-rays revealed no pneumothorax or hemothorax and no pneumoperitoneum. In light of the above findings, the patient was admitted to the hospital for observation.

Eighteen hours after admission, the patient's temperature had risen to 100.8° F and his white blood cell count had climbed to 16,000 cells/mm<sup>3</sup>. On physical examination, the patient's subjective complaints and objective findings had appeared to be limited only to the wounds themselves; because of his elevated temperature and white blood cell count, the patient was taken to the operating room for laparoscopic exploration.

Pneumoperitoneum was created through a 10- to 11-mm sheath placed infraumbilically using the

---

Received February 11, 1992; accepted June 9, 1992.  
From the Department of Surgery, The Medical College of Wisconsin, Milwaukee, Wisconsin, U.S.A.

Address correspondence and reprint requests to Dr. Constantine T. Frantzides, Department of Surgery, Medical College of Wisconsin, 8700 W. Wisconsin Avenue, Milwaukee, WI 53226, U.S.A.

open technique. The videolaparoscope was then placed through this sheath. Under direct vision, a 5-mm cannula was then placed in the right midabdomen. Initial laparoscopic inspection of the abdominal cavity revealed no free intra-abdominal fluid.

There was violation of the peritoneum by the anterior stab wound. Thorough inspection of the left hemidiaphragm and liver, anterior and lateral aspects of the spleen, and transverse and left colon revealed no injury. Fibrinous exudate was found on the anterior wall of the stomach. Inspection revealed two gastric lacerations high on the fundus. Each laceration measured 8 to 10 mm in length, and they were separated by 1 cm of normal stomach. After entering the lesser sac through an opening in the gastrocolic omentum, the posterior gastric wall was explored and found to be normal.

After the decision to attempt laparoscopic repair was made, another sheath was introduced into the right upper abdomen for placement of a laparoscopic retractor. The left lobe of the liver was then elevated off the stomach. A 12-mm sheath was placed in the left upper quadrant near the midline. Using an atraumatic grasper placed through the lower right 5-mm sheath, the anterior wall of the stomach was tented-up in the region of the lacerations. An Endo stapler (Ethicon, Sommerville, NJ, U.S.A.) was then introduced through the 12-mm sheath, and each laceration was closed using three titanium sta-

ples (Fig. 1). An omental patch was then pulled up over the repairs and secured in place with additional staples. At this point, the upper abdomen was filled with enough saline to cover the repairs. The stomach was then distended with air introduced through the nasogastric tube. The absence of bubbling through the repairs indicated secure closure. The saline was then removed, a drain placed near the repair, and the procedure terminated.

The patient had an uneventful recovery. By post-operative day 4, he was tolerating a regular diet and was discharged.

## DISCUSSION

Management of abdominal stab wounds varies from institution to institution. Whereas hemodynamic instability and peritonitis are obvious indications for operation, many patients have stable vital signs and equivocal findings on abdominal examination. These patients present diagnostic and treatment dilemmas. A number of diagnostic strategies have been developed to reduce the incidence of unnecessary laparotomy in such patients.

Some authors have recommended exploration of anterior abdominal stab wounds under local anesthesia. If a wound extends to the posterior rectus sheath, laparotomy is performed. This management protocol results in a large number of unnecessary laparotomies (1). Another technique to determine need for laparotomy is probing of the wound tract. If peritoneal penetration has occurred, laparotomy ensues. This technique also results in many unnecessary explorations and is often unreliable (1).

Recently, the use of peritoneal lavage has come into vogue as a technique for evaluating abdominal stab wounds. Patients with stable vital signs and equivocal exams are usually subjected to peritoneal lavage. Although lavage is sensitive in detecting intra-abdominal blood, bile, or enteric contents, a dilemma frequently arises if results are near the cutoff line between positive and negative. In fact, there is little agreement on exactly where to set the sensitivity level (12,13). In one report from Feliciano et al. (14) 19% of patients considered to have a positive peritoneal lavage underwent either a nontherapeutic or negative laparotomy. Not every hemoperitoneum leads to a therapeutic celiotomy (15,16).

Finally, some recommend in-hospital observation after anterior abdominal stab wounds to determine the need for laparotomy (4,5). No specific diagnostic tests or procedures are performed other than physical examination. Those who favor adjunctive

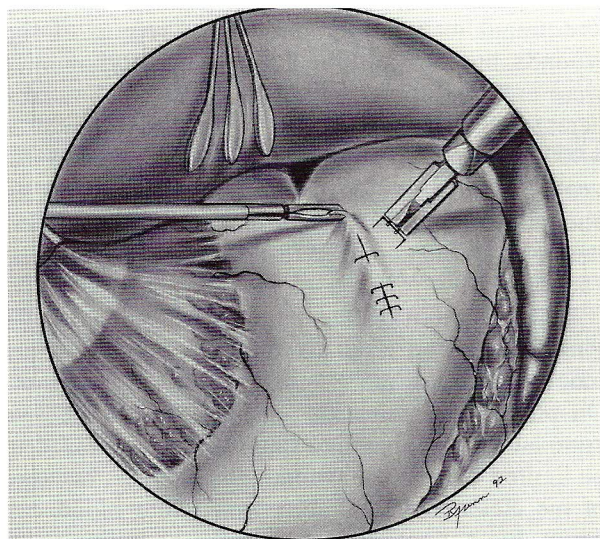
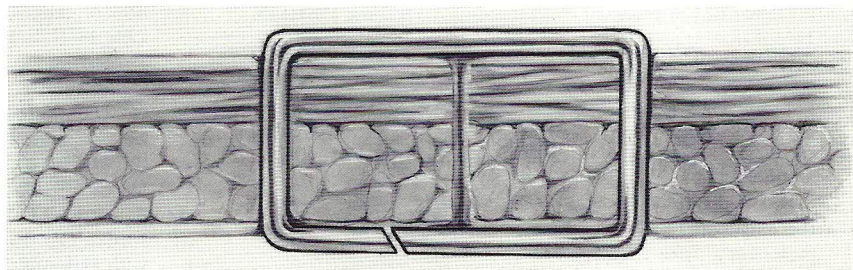


FIG. 1. Laparoscopic view of gastric stab wounds. Retractor is on the left lobe of the liver. A grasper placed through the right midabdominal sheath is used to tent-up the anterior stomach wall for application of staples.



FIG. 2. Cross-sectional view of staple in place on gastric wall illustrating the ability of the staple to appose the edges of the wound.



procedures to determine peritoneal penetration note a high rate of unnecessary laparotomy, based on physical findings, when abdominal exploration is undertaken (12). Better diagnostic tests are needed if unnecessary laparotomies are to be avoided. Laparoscopy may help in this respect.

Laparoscopy has gained wide use in elective diagnosis and treatment of intra-abdominal pathology; however, it has not been widely used in the trauma setting despite reports of its safety and accuracy in defining intra-abdominal injury. Carnival et al. (9) used laparoscopy in the evaluation of 15 patients with penetrating abdominal trauma and five patients with blunt trauma. All patients were clinically stable and had equivocal abdominal examinations. Laparotomy was avoided in 12 of the 20 patients based on findings at laparoscopy. No complications attributable to laparoscopy occurred, and no false-negative laparoscopic explorations were done. In this series, patients who underwent laparoscopy only spent an average of 4.5 days in the hospital, and those who underwent laparotomy spent a minimum of 7 days in the hospital.

Gazzaniga et al. (8) performed laparoscopy in 13 patients with penetrating abdominal trauma. Nine patients subsequently underwent laparotomy based on laparoscopic findings, and four were spared laparotomy based on findings at laparoscopy. In this series, there was one questionable false-negative laparoscopic finding in a patient with a left lower chest gunshot wound that required delayed operative intervention.

Finally, Berci et al. (10) published their experience with laparoscopic evaluation of nine cases of abdominal stab wounds. By using diagnostic laparoscopy, laparotomy was avoided in six cases. No false-negative laparoscopic examinations were reported in this series.

Based on the literature and our experience with this and other cases, it appears that laparoscopy certainly is useful in avoiding unnecessary laparotomy in stable patients with questionable physical

findings. The low incidence of false-negative laparoscopic exploration is encouraging. Until this time, however, it has been used only as a diagnostic tool. Improved optics, better instrumentation, and greater familiarity with laparoscopic techniques will expand the role of laparoscopy in trauma as illustrated by the case presented here. Although the gastric stab wounds were not very large, they were situated high on the fundus. Closure via laparotomy would have required a generous midline incision to expose this area for repair. Using the laparoscope, we were able to explore the left upper quadrant thoroughly and repair the stab wounds through miniscule puncture wounds.

The stapling device used for closure of the wounds is actually designed for use in laparoscopic hernia repair. We have, however, used it in the laboratory to close pyloroplasty wounds with good results. Figure 2 illustrates the fashion in which the staple approximates tissue for closure.

Caution and a low threshold for conversion to formal laparotomy are obviously recommended at this early stage; however, as illustrated by this case report, innovative techniques and instrumentation will make possible the management of selected injuries through the laparoscope. These innovations will decrease patient pain, hospital time, cost, and convalescence.

## REFERENCES

1. Sirinek KR, Page CP, Root HD, Levine BA. Is exploratory celiotomy necessary for all patients with truncal stab wounds? *Arch Surg* 1990;125:884-8.
2. Petersen SR, Sheldon GF. Morbidity of a negative finding at laparotomy in abdominal trauma. *Surg Gynecol Obstet* 1979; 148:23-6.
3. Demetriades D, Rabinowitz B. Indications for operation in abdominal stab wounds: A prospective study of 651 patients. *Ann Surg* 1987;205:129-32.
4. Huizinga WKJ, Baker LW, Mtshali ZW. Selective management of abdominal and thoracic stab wounds with established peritoneal penetrations. The eviscerated omentum. *Am J Surg* 1987;153:564-8.
5. Shorr RM, Gottlieb MM, Webb K, Ishiguro L, Berne TV. Selective management of abdominal stab wounds: im-

- portance of the physical examination. *Arch Surg* 1988;123:1141-5.
6. Zubowoski R, Nallathambi M, Ivatury R, Stahl W. Selective conservatism in abdominal stab wounds: the efficacy of serial physical examination. *J Trauma* 1988;28:1665-8.
  7. Robin AP, Andrews JR, Lange DA, Roberts RR, Moskalm, Baret J. Selective management of anterior abdominal stab wounds. *J Trauma* 1989;29:1684-9.
  8. Gazzaniga AB, Stanton WW, Bartlett RH. Laparoscopy in the diagnosis of blunt and penetrating injuries to the abdomen. *Am J Surg* 1976;131:315-8.
  9. Carnival N, Baron N, Delany HM. Peritoneoscopy as an aid in the diagnosis of abdominal trauma: a preliminary report. *J Trauma* 1977;17:634-41.
  10. Berci G, Dunkelman D, Michel SL, Sanders G, Wahlstrom E, Morgenstern L. Emergency minilaparoscopy in abdominal trauma: An update. *Am J Surg* 1983;146:261-5.
  11. Sosa JL, Sims D, Martin L, Zeppar R. Laparoscopic evaluation of tangential abdominal gunshot wounds. *Arch Surg* 1992;127:109-10.
  12. Thompson JS, Moore EE, Van Duzer-Moore SV, Moore JB, Galloway AC. The evolution of abdominal stab wound management. *J Trauma* 1980;20:478-84.
  13. Medina MM, Ivatury RR, Stahl WM. Omental evisceration through an abdominal stab wound: is exploratory laparotomy mandatory? *Can J Surg* 1983;118:57-9.
  14. Feliciano DV, Bitondo CG, Steed G, Mattox KL, Burch JM, Jordan GL. Five hundred open taps or lavages in patients with abdominal stab wounds. *Am J Surg* 1984;148:772-7.
  15. Levin A, Goser P, Nance F. Surgical restraint in the management of hepatic injury: a review of Charity Hospital experience. *J Trauma* 1978;18:399-404.
  16. Demetriades D, Rabinowitz B, Sofianos C. Non-operative management of penetrating liver injuries: a prospective study. *Br J Surg* 1986;73:736-7.