

## Laparoscopic Versus Conventional Fundoplication

CONSTANTINE T. FRANTZIDES, M.D., Ph.D., F.A.C.S., and  
MARK A. CARLSON, M.D.

### ABSTRACT

The operative and short-term results of 29 patients who had an open fundoplication were compared to 36 patients who had a laparoscopic fundoplication. The operative time was  $2.8 \pm 0.4$  and  $3.1 \pm 0.3$  h for the open and laparoscopic procedure, respectively. The length of hospital stay was  $9.2 \pm 0.7$  days for the open and  $1.8 \pm 0.2$  days for the laparoscopic. There were five complications in the open group and one in the laparoscopic group. The follow-up period was 3–32 months and all patients had a barium swallow and esophago-gastroduodenoscopy (EGD) for postoperative evaluation. All patients had resolution of esophagitis on follow-up endoscopy, were free of reflux symptoms, and no longer required antireflux medication. Laparoscopic Nissen fundoplication has an operative time that is comparable to the open procedure. The complication rate for laparoscopic fundoplication is acceptable. Patients undergoing a laparoscopic fundoplication have a shorter hospital stay compared to patients with an open procedure. The short-term outcome for the laparoscopic fundoplication group was excellent.

### INTRODUCTION

Laparoscopic fundoplication has been performed for nearly 4 years.<sup>1–3</sup> Its acceptance as the procedure of choice for a patient in whom an operation is indicated for gastroesophageal reflux disease (GERD) has not been universal. This may in part be due to a relative lack of literature documenting the feasibility and efficacy of laparoscopic fundoplication.

In response to this, we would like to contribute our experience to the small but growing body of evidence<sup>4–10</sup> supporting the use of laparoscopic fundoplication in the patient who requires operative intervention for GERD. We have collected data on a group of patients with laparoscopic fundoplication and have compared this to data from a group with open fundoplication. We believe that the laparoscopic approach to fundoplication results in immediate benefit to the patient in terms of decreased hospital stay, without putting the patient at an increased operative risk and without compromising the effectiveness of the procedure.

### PATIENTS AND METHODS

The study was conducted in an academic setting consisting of a county hospital and a referral center. Each of the two study groups consisted of consecutive patients taken from the same time period (1992–1994). The samples were not generated randomly, but were a result of referral patterns through which patients ob-

tained surgical consultation for their GERD. All laparoscopic funduplications were performed by one staff surgeon with a resident surgeon as first assistant. All open funduplications were performed by resident surgeons with the supervision and active participation of five different staff surgeons.

During the study period, 36 patients underwent a laparoscopic fundoplication and 37 had the open technique. The fundoplication represented a second procedure for GERD in 8 patients of the open group, and these patients were excluded from the study. In addition, patients with large hiatal hernia (>5 cm) were excluded from the study. The average age for the laparoscopic group was 46 years and for the open group 48; the age range was 23–83 and 22–77, respectively. The male/female ratio was 22:14 in the laparoscopic group and 17:12 in the open group. Ten patients in the laparoscopic group and 12 in the open group had previous abdominal surgery. Five patients in the laparoscopic group underwent a simultaneous procedure (4 cholecystectomies, 1 enterolysis).

All patients in this study had symptoms of GERD that were not controlled by maximum medical therapy. All patients underwent endoscopy preoperatively, and all had evidence of erosive esophagitis. Five of the patients in the laparoscopic group and seven in the open group had Barrett's esophagus. Preoperative manometry and 24-h esophageal pH monitoring was performed in 14 patients who had dysphagia or odynophagia.

Patients who underwent open fundoplication required 10 mg of IM morphine sulfate every 3 h for 3–4 postoperative days for effective analgesia. The laparoscopic group was treated with 30 mg of IM ketorolac tromethamine every 6 h for 1 day.

All antireflux medications were discontinued the day before surgery. The follow-up period ranged from 3–32 months, and all patients had at least one EGD and a barium swallow 3–6 months postoperatively. At quarterly clinical examinations, patients were evaluated for symptoms of reflux, dysphagia, flatulence, and treatment satisfaction.

The unpaired *t*-test was used to test for significant difference in operative time and length of stay. The level of significance for values was  $p < 0.05$ .

## TECHNIQUE

After induction of general anesthesia and preparation of the abdomen, pneumoperitoneum is established utilizing the open technique with the Hasson cannula. The Hasson is placed through a supraumbilical midline incision, at the midpoint between the xiphoid and the umbilicus. Four additional 10-mm trocars are placed, two along the left subcostal margin, one in the subxiphoid region, and one along the right subcostal margin in the midclavicular line (Fig. 1). For those cases in which the short gastric vessels are to be divided with a linear stapler-cutter, a 12-mm trocar is placed at point 4 (Fig. 1).

The patient is placed in a modified lithotomy position with the knees slightly flexed and the operating table in reverse Trendelenburg position. The surgeon stands between the patient's legs, the first assistant stands to the left, and the second assistant to the right of the patient. The first assistant retracts the left lobe of the liver to the right with an inflatable laparoscopic retractor (Cabot Medical, Longhorne, PA) introduced through the subxiphoid port (port 2). In addition, the first assistant retracts the stomach inferolaterally with a Babcock forceps inserted through the lateral left subcostal port (port 5). With this maneuver the gastroesophageal junction is visualized.

The surgeon operates via the third and fourth ports (Fig. 1). A nonratcheted grasping forceps is introduced through the third port and laparoscopic scissors or hook electrocautery through the fourth port. Diathermy is used only for the division of the peritoneum. The peritoneum at the gastroesophageal junction is opened and the esophagus is identified (Fig. 2). In obese patients the accurate identification of the esophagus can be facilitated with the introduction of a lighted bougie into the esophagus by the anesthesiologist. The transilluminated esophagus can be safely mobilized primarily by blunt dissection using a palpation probe. During this dissection the esophageal hiatus is exposed and the right crus and posterior vagus are identified. In those patients in whom the upper pole of the spleen is very close to the gastroesophageal junction, the short gastric vessels are first taken down before completely mobilizing the esophagus, thus avoiding iatrogenic splenic injury. For the creation of the window posterior to the esophagus we utilize a 30° laparoscope, which allows better visualization of this region.

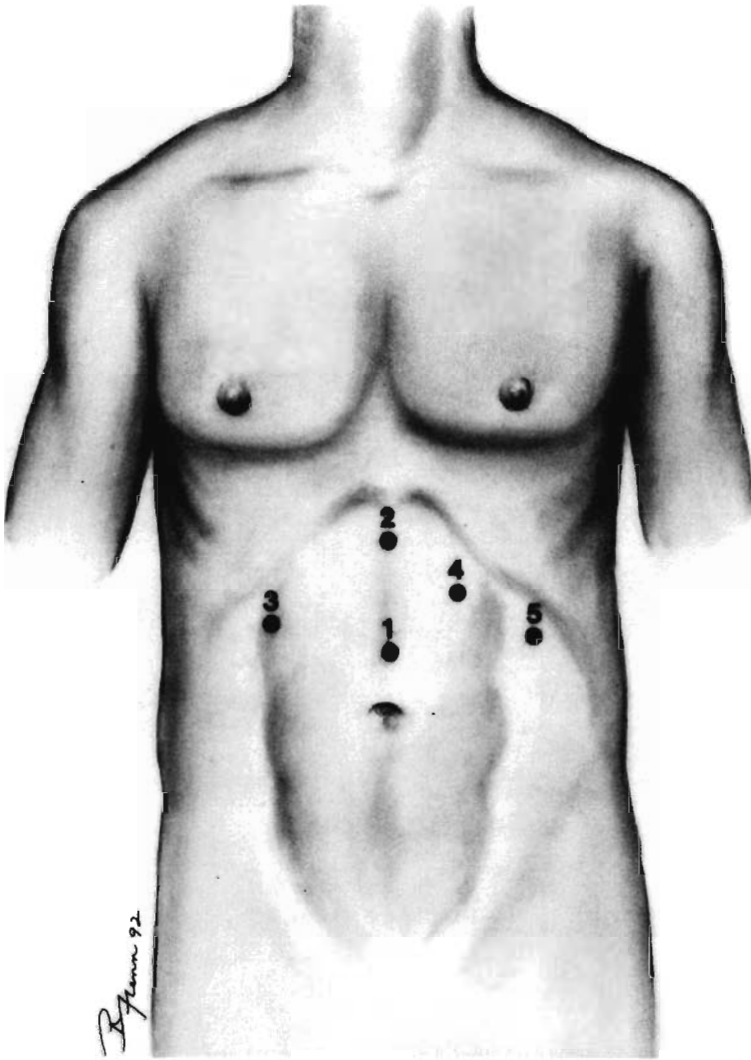


FIG. 1. Diagrammatic representation of port placement for laparoscopic fundoplication.

The next step in the procedure is the ligation of short gastric vessels. In order to facilitate division of these vessels the stomach is retracted to the right by a Babcock forceps introduced through port 3. An inflatable atraumatic retractor inserted through port 5 is used to gently retract the gastrosplenic omentum to the left (Fig. 3). A right-angle dissecting forceps is utilized through port 4 to isolate the short gastric vessels. These vessels are doubly clipped and divided. A right-angle clip applier (Origin Medsystems, Inc., Menlo, CA) facilitates and expedites the ligation of the short gastric vessels. Alternatively, a small opening can be made in the gastrosplenic omentum and a vascular stapler-cutter can be fired. This is an easy but expensive method of ligating the short gastric vessels.

In those patients with a hiatal hernia, two to three interrupted sutures are applied on the right and left bundles of the right crus to close the hiatus posterior to the esophagus (Fig. 4A). A 45–50 French Maloney dilator is inserted into the esophagus to avoid undue constriction.

A Babcock forceps passed posterior to the esophagus is used to grasp the gastric fundus. The fundus is brought around the esophagus to form the wrap. A 4–5-cm fundoplication is completed with two or three interrupted 2–0 nonabsorbable sutures, taking bites of the stomach (Fig. 4B). To prevent slippage of the wrap, the upper part of the crus is incorporated in the first (upper) stitch, and a small bite of the gastroesophageal junction in the last stitch (lower). Before evacuation of the pneumoperitoneum the fascial de-

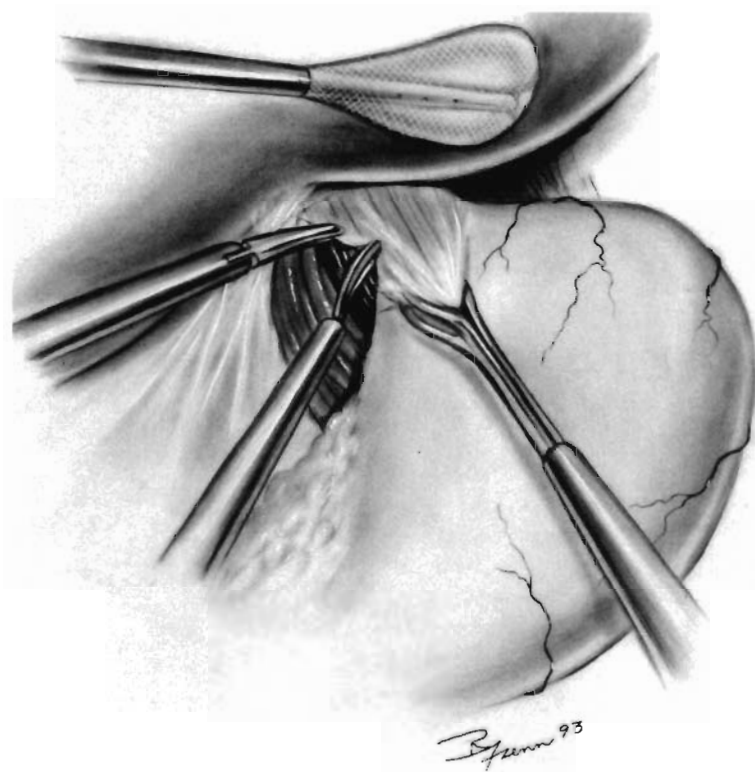


FIG. 2. Opening of the peritoneum at the gastroesophageal junction.

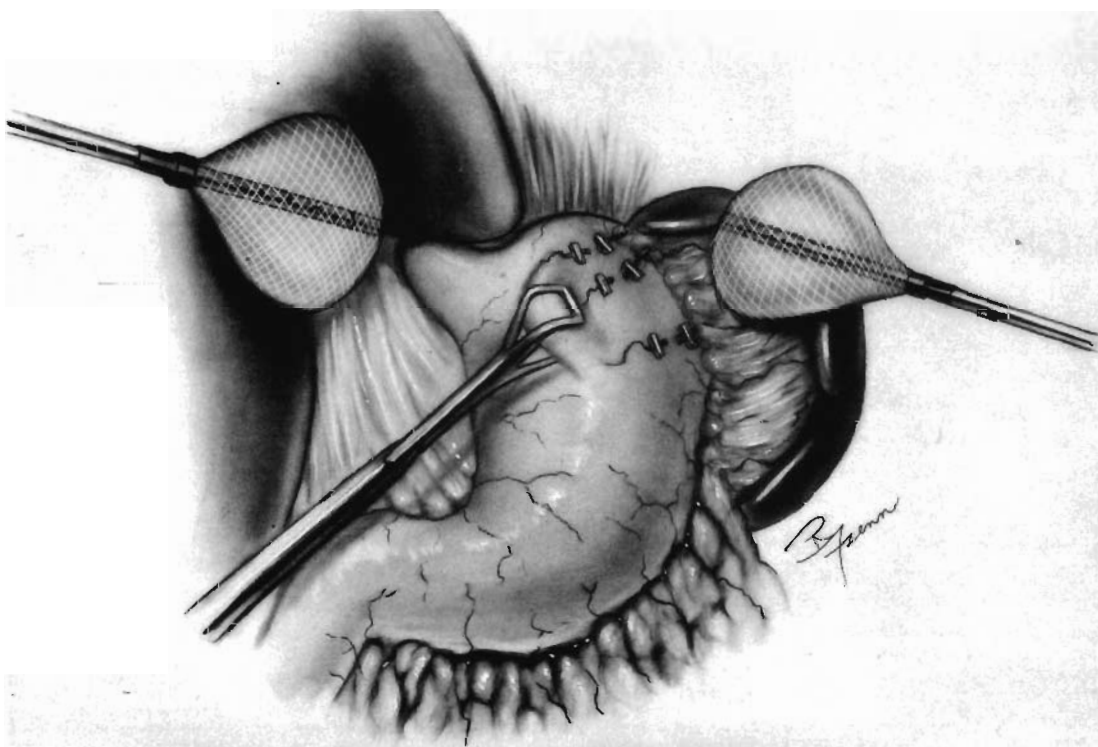


FIG. 3. Ligation and division of the short gastric vessels.

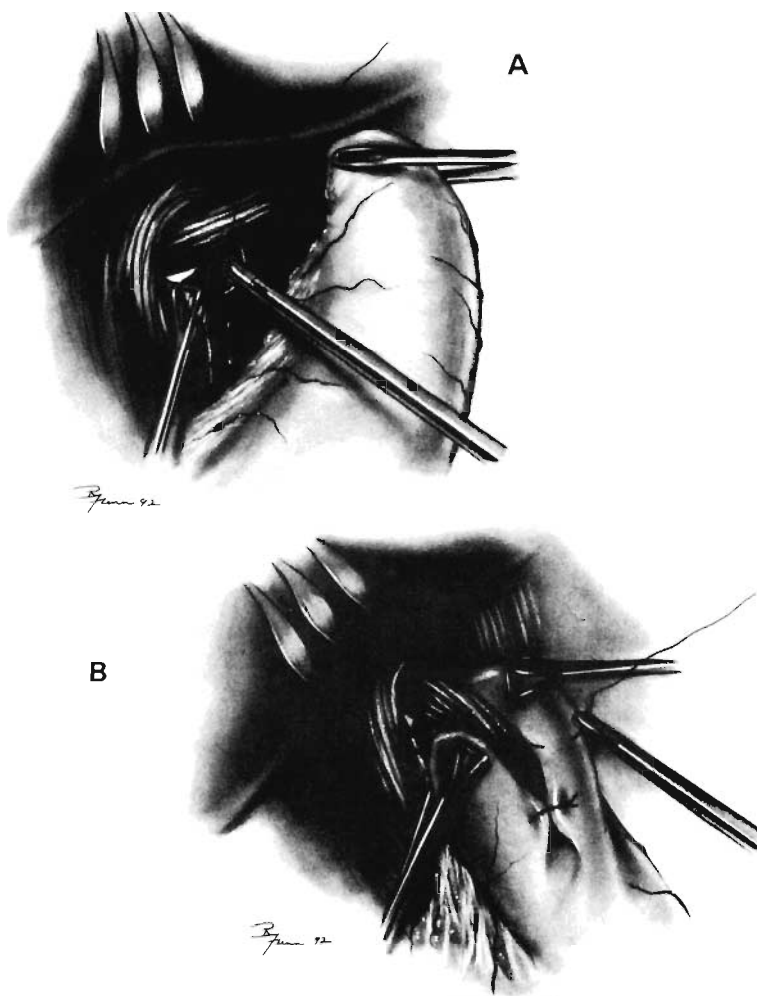
fects at ports 4 and 5 are closed utilizing a fascial closer. The fascia at port 1 is closed by placing two or three nonabsorbable interrupted sutures after all trocars are removed and pneumoperitoneum evacuated.

The open funduplications were performed in the same fashion as the laparoscopic with the only difference being that 25 of the open were combined with a gastrostomy.

## RESULTS

There was no significant difference in operative time between the laparoscopic ( $3.1 \pm 0.3$  h) and open ( $2.8 \pm 0.4$  h) fundoplication. The length of hospital stay for the laparoscopic procedure ( $1.8 \pm 0.2$  days) was significantly shorter than for the open procedure ( $9.2 \pm 0.7$  days) (Table 1).

There were five complications (17.2%) in the open group: three splenic lacerations that required splenectomies, one gastrocutaneous fistula (at the gastrostomy site), and one upper gastrointestinal bleed. One complication (2.7%) occurred in the laparoscopic group: a gastric perforation at the point where the Babcock forceps had been placed. This operation was converted to open, the perforation was repaired, and the fundoplication completed. The patient had an uneventful recovery, without any consequences from the complication.



**FIG. 4.** (A) Closure of the posterior opening of the esophageal hiatus. (B) Anchoring of the fundus to complete the wrap.

TABLE I. FUNDOPLICATION

	<i>Number of patients</i>	<i>Operative time (hrs)</i>	<i>Hospital stay (days)</i>	<i>Complications</i>
Conventional	29	2.8 ± 0.4	9.2 ± 0.7	5 (17.2%)
Laparoscopic	36	3.1 ± 0.3	1.8 ± 0.2	1 (2.7%)

Patients were followed up for 3–32 months and underwent upper gastrointestinal and barium swallow within 3–6 months postoperatively. All had resolution of esophagitis (Visick I and II) and reflux as demonstrated by endoscopy and barium swallow studies. At clinic follow-up two patients in the laparoscopic group complained of dysphagia within the first postoperative month; one of these patients had spontaneous resolution of the problem. The other patient was demonstrated preoperatively to have mild esophageal dysmotility on manometry, and a loose fundoplication was constructed. The dysphagia continued for 3 months but eventually resolved with administration of bethanechol.

## DISCUSSION

Herein we have presented and compared the results of two nonrandomized groups of patients undergoing fundoplication; one group operated on through the laparoscope and the other done open.

The laparoscopic group had a similar operative time and a shorter length of hospitalization compared to the open group. In addition, the laparoscopic group experienced less pain as evidenced by the minimal use of analgesics postoperatively. The complication rate was lower in the laparoscopic group. The one complication that occurred in the laparoscopic group was an instrument-inflicted perforation of the fundus. This points to the need for less traumatic instrumentation.

The short-term outcome in the laparoscopic group was excellent with resolution of esophagitis and symptoms in all patients. We recognize that the two groups of patients are not absolutely comparable because the open procedures were done by surgeons in training. In addition, the open group was subjected to a gastrotomy—a tradition in our department. Nevertheless, our results indicate that the laparoscopic fundoplication is feasible, safe, and effective. We believe that the laparoscopic approach should be preferred for the surgical treatment of GERD, and that the open approach should be reserved for reoperation on the failed fundoplication.

The favorable experience with laparoscopic fundoplication that we and others<sup>4–10</sup> have obtained is due to proper patient selection for fundoplication; laparoscopic replication of an operation which, performed in the conventional (open) manner, has been shown to be an effective treatment for medically unmanageable GERD<sup>11–14</sup>; and careful, meticulous conduct of the operation with minimal use of diathermy.

## REFERENCES

1. Geagea T: Laparoscopic Nissen's fundoplication: preliminary report on ten cases. *Surg Endosc* 1991;5:170–173.
2. Dallemagne B: Laparoscopic Nissen fundoplication: preliminary report. *Surg Laparosc Endosc* 1991;1:138–143.
3. Bagnato VJ: Laparoscopic Nissen fundoplication. *Surg Laparosc Endosc* 1992;2:188–190.
4. Bittner HB, Meyers WC, Brazer SR, Pappas TN: Laparoscopic Nissen fundoplication: operative results and short-term follow-up. *Am J Surg* 1994;167:193–200.
5. Cadriere GB, Houben JJ, Bruyuns J, et al: Laparoscopic Nissen fundoplication: technique and preliminary results. *Br J Surg* 1994;81:400–403.
6. Hinder RA, Filipi CJ: Laparoscopic Nissen fundoplication. In Frantzides CT (ed.) *Laparoscopic and Thoracoscopic Surgery*. Mosby Year-book, Inc., 1994.

## LAPAROSCOPIC VS. CONVENTIONAL FUNDOPLICATION

7. McKernan JB, Laws HL: Laparoscopic Nissen fundoplication for the treatment of gastroesophageal reflux disease. *Am Surg* 1994;60:87-93.
8. Nowzaradan Y, Barnes P: Laparoscopic Nissen fundoplication. *J Laparoendosc Surg* 1993;3:429-438.
9. Weerts JM, Dallemagne B, Hamoir E, et al.: Laparoscopic Nissen fundoplication: detailed analysis of 132 patients. *Surg Laparosc Endosc* 1994;3:359-364.
10. Swanstrom L, Wayne R: Spectrum of gastrointestinal symptoms after laparoscopic fundoplication. *Am J Surg* 1994;167:538-541.
11. Grande L, Toledo-Pimentel V, Manterola C, Lacima G, Ros E, Garcia-Valdecasas JC, Fuster J, Visa J, Pera C: Value of Nissen fundoplication in patients with gastroesophageal reflux judged by long-term symptom control. *Br J Surg* 1994;81:548-550.
12. Luostarinen M, Isolauri J, Laitinen J, Koskinen M, Keyrilainen O, Markkula H, Lehtinen E, Uusitalo A: Fate of Nissen fundoplication after 20 years. A clinical, endoscopic, and functional analysis. *Gut* 1993;34:1015-1020.
13. Dunnington GL, De Meester TR: Outcome effect of adherence to operative principles of Nissen fundoplication by multiple surgeons. The Department of Veterans Affairs Gastroesophageal Reflux Disease Study Group. *Am J Surg* 1993;166:654-657.
14. Luostarinen M: Nissen fundoplication for reflux esophagitis. Long-term clinical and endoscopic results in 109 of 127 consecutive patients. *Ann Surg* 1993;217:329-337.

Address reprint requests to:  
*Constantine T. Frantzides, M.D., Ph.D.*  
*Associate Professor*  
*Department of Surgery*  
*Medical College of Wisconsin Avenue*  
*9200 West Wisconsin Avenue*  
*Milwaukee, WI 53226*