

# Canine Intestinal Myoelectric Activity after Open versus Laparoscopically Assisted Right Hemicolectomy

Mark A. Carlson, MD, Constantine T. Frantzides, MD, PhD, FACS, Milwaukee, Wisconsin

**BACKGROUND:** It is a common belief that a laparoscopic procedure results in a shorter duration of postoperative ileus compared with the equivalent open procedure. This study was undertaken to determine whether laparoscopically assisted right hemicolectomy in the dog results in a shorter duration of ileus compared with open right hemicolectomy.

**METHODS:** Eight bipolar serosal electrodes (4 on the small bowel, 4 on the left colon) were implanted in each dog ( $n = 10$ ). Three weeks after electrode implantation baseline recording was made for 5 days; then 5 dogs underwent laparoscopically assisted right hemicolectomy and 5 underwent open right hemicolectomy. Myoelectric activity was recorded continuously for 72 hours postoperatively. Tracings were analyzed for the time of reappearance, duration, migration velocity, and cycle length of phase 2, phase 3, and the migrating colonic complex. The criteria used for the resolution of postoperative ileus were the return of phase 2, phase 3, and the migrating colonic complex.

**RESULTS:** All dogs had temporary loss of organized myoelectric activity postoperatively. The mean reappearance time (minutes  $\pm$  standard deviation) for phase 3 was  $857 \pm 574$  versus  $761 \pm 600$ ; the phase 2 reappearance time was  $1,845 \pm 610$  versus  $1,590 \pm 668$ ; and the migrating colonic complex reappearance time was  $534 \pm 365$  versus  $572 \pm 552$ , open versus laparoscopically assisted right hemicolectomy, respectively. The times were not different (Wilcoxon rank sum test,  $P > 0.05$ ). The time required for phase 3, phase 2, and the migrating colonic complex to attain preoperative configuration also was not different between the open and laparoscopically assisted group.

**CONCLUSION:** Myoelectric resolution of postoperative ileus did not occur earlier in the dog under-

going laparoscopically assisted right hemicolectomy compared to the dog undergoing open right hemicolectomy. This data does not support the hypothesis that a laparoscopically assisted colectomy results in a shorter duration of postoperative ileus than the equivalent open procedure. *Am J Surg.* 1997;174:79-82. © 1997 by Excerpta Medica, Inc.

The patient undergoing a laparoscopic colectomy usually has a shorter hospital stay compared to the patient undergoing the open operation,<sup>1</sup> but it is not clear whether the former patient has a shorter period of ileus. A common clinical impression is that ileus is shorter after laparoscopic cholecystectomy compared to open cholecystectomy. However, it has been observed in the dog that the recovery of organized intestinal myoelectric activity after open versus laparoscopic cholecystectomy is not different.<sup>2</sup> We wanted to determine whether this result would extend to a different operation. Here we report a comparison of postoperative myoelectric activity in the small and large bowel in dogs undergoing open versus laparoscopically assisted right hemicolectomy.

Ten mongrel dogs were studied, each weighing 25 to 35 kg. The study protocol was approved by our Animal Welfare Committee. General anesthesia (pentobarbital sodium, 25 mg/kg intravenously) was used for all operations; each dog was fasted for 12 hours preoperatively. Eight bipolar electrodes were placed through a midline incision, four on the small intestine (20 cm apart, with the first 50 cm from the ligament of Treitz) and four on the left colon (10 cm apart), as described previously.<sup>2</sup> The electrode wires exited through a cannula out the left flank. After a 3-week recovery period, fasted myoelectric activity was recorded on a polygraph recorder (Grass model 7; Grass Institute, Quincy, MA) for 6 to 8 hours per day for 5 days (baseline period).

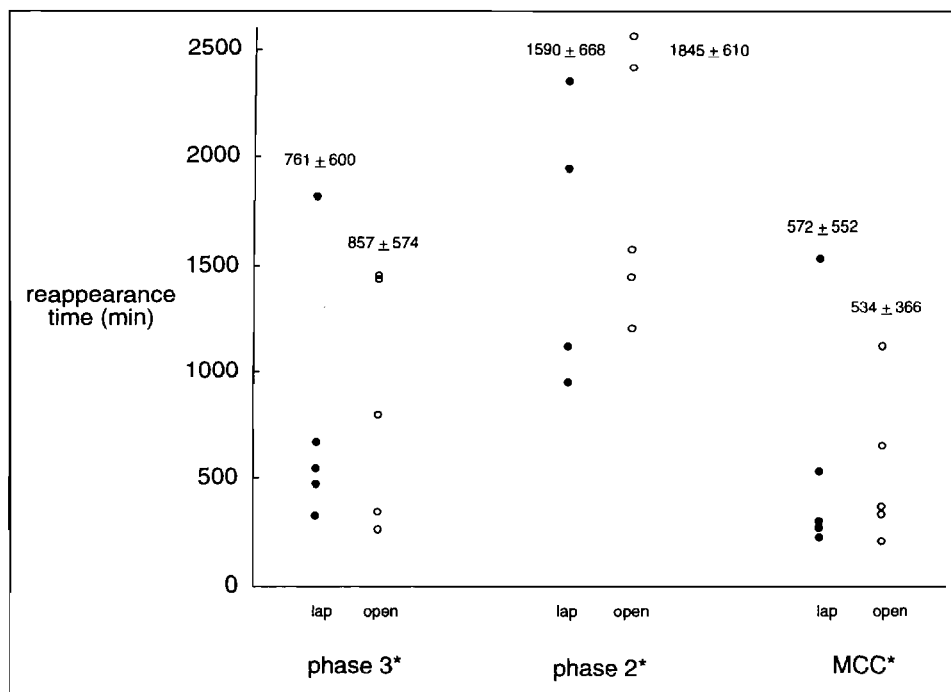
Open right hemicolectomy ( $n = 5$ ) was done through the previous midline incision (length 24 cm). A side-to-side ileocolostomy was constructed with a linear stapler (Ethicon-Endosurgery, Cincinnati, Ohio). The incision was closed with running 2-0 nylon (fascia) and 3-0 polyglycolic acid (hide). Laparoscopically assisted right hemicolectomy ( $n = 5$ ) was performed with four 10-mm trocars. Mobilization was done with hook cautery. An extracorporeal stapled anastomosis was made using a trocar incision (extended to 4 cm) in the right upper quadrant. The trocar incisions were closed similarly as above. Average operating time was 120 and 140 min, open and laparoscopically assisted right hemicolectomy, respectively. No dog received any analgesic after colectomy. Recording of myoelectric ac-

From the Department of Surgery, Medical College of Wisconsin, Milwaukee, Wisconsin.

Presented in part at the SSAT Sponsored Clinical Symposium on Laparoscopic Surgery, the 37th Annual Meeting of the Society for Surgery of the Alimentary Tract, San Francisco, CA, May 19-22, 1996.

Requests for reprints should be addressed to Constantine T. Frantzides, MD, Department of Surgery, Director of Minimally Invasive Surgery Center, Medical College of Wisconsin, 9200 West Wisconsin Avenue, Milwaukee, Wisconsin 53226.

Manuscript submitted June 11, 1996 and accepted in revised form September 26, 1996.



**Figure 1.** Time of initial appearance for phase 3, phase 2, and the migrating colonic complex after open ( $n = 5$ ) versus laparoscopically assisted ( $n = 5$ ) right hemicolectomy in the dog. The value above each column of data is the mean  $\pm$  standard deviation. \* $P > 0.05$ , Wilcoxon rank sum test; open = open right hemicolectomy; lap = laparoscopically assisted right hemicolectomy; MCC = migrating colonic complex.

tivity was continuous for 72 hours postoperatively, during which the dogs had access to water only.

The reappearance time of phase 2, phase 3, and the migrating colonic complex was determined by visual analysis of the myoelectric record. Phase 2 was defined as spike activity that occurred on 5% to 95% of small intestine slow waves, preceded phase 3, and was present through all four small bowel electrodes. Phase 3 was defined as spike activity occurring on >95% of small intestinal slow waves and that migrated through all four small bowel electrodes. The migrating myoelectric complex was defined as a phase 2-phase 3 sequence, which migrated through all four small bowel electrodes. The migrating colonic complex was defined as spike activity occurring on >50% of colonic slow waves, and that migrated through at least three adjacent colonic electrodes.

The duration of a migrating wavefront was measured in the first in which the wavefront first appeared. Migration velocity was measured over two adjacent interelectrode lengths. Cycle length was measured from the beginning of one migrating wavefront to the beginning of the next in the electrode in which the wavefront first appeared. Data are reported as mean  $\pm$  standard deviation, and were compared with the unpaired  $t$  test and the Wilcoxon rank sum test, with  $P < 0.05$  accepted as significant.

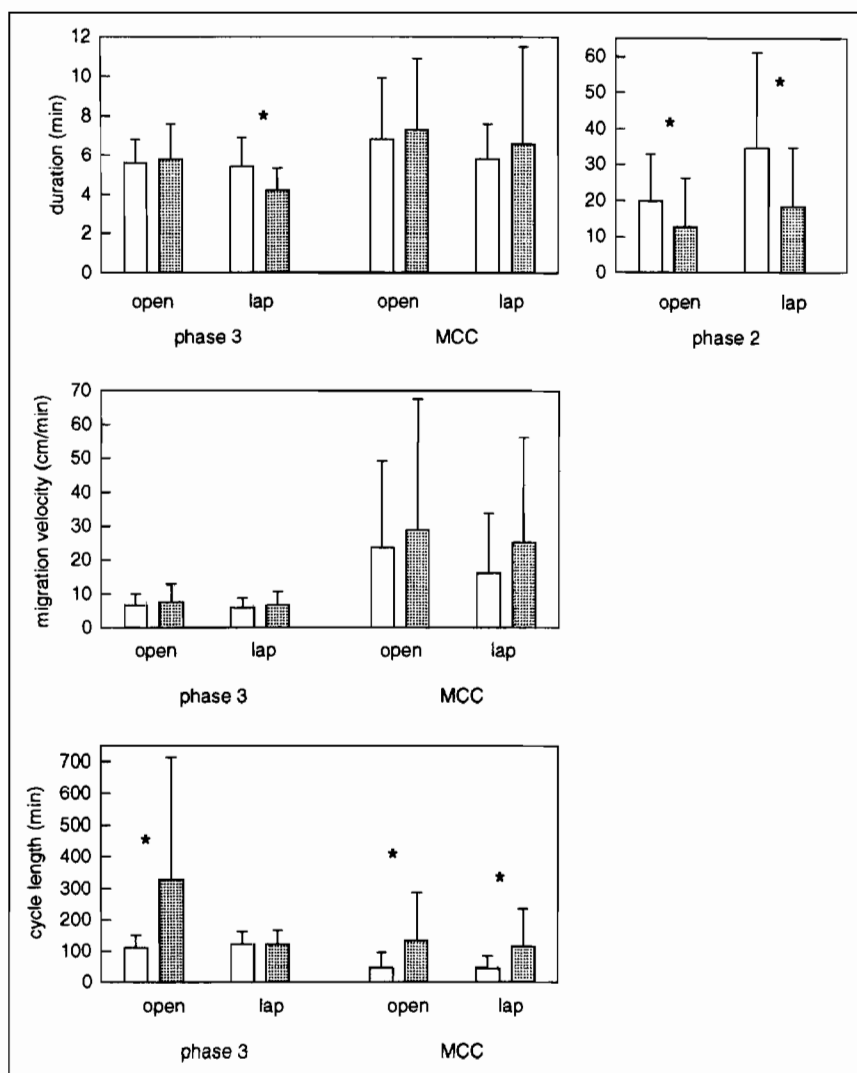
All dogs underwent operation without complication. A typical record of preoperative fasted myoelectric activity for this model has been published.<sup>2</sup> Postoperatively spike activity was absent in all dogs, with only slow wave activity present in both the small bowel and colon. Migrating phase 3 activity reappeared first without phase 2, and then phase 2 reappeared with phase 3 to form the migrating myoelectric complex. The migrating colonic complex returned independent of the above events. The myoelectric recovery

from ileus resembled a published record of canine myoelectric activity after cholecystectomy.<sup>2</sup>

The time of reappearance for the initial phase 3, and phase 2, and the migrating colonic complex was not different after open versus laparoscopically assisted right hemicolectomy (Figure 1). The initial postoperative wavefronts, however, did not closely resemble the preoperative wavefronts; that is, the initial postoperative myoelectric parameters (duration, migration velocity, and cycle length) were not all within one standard deviation of the preoperative myoelectric parameters (Figure 2). The time of return for wavefronts of normal configuration (defined as the time at which wavefront duration, migration velocity, and cycle period attained a value for two consecutive cycles within one standard deviation of the preoperative value) was not different between the two groups (Figure 3).

The recovery time of phase 3, phase 2, and the migrating colonic complex in the dog after open versus laparoscopically assisted right hemicolectomy was not different. Given the amount of variability in the means, the number of dogs in each group, and by letting  $\alpha = 0.05$  and  $\beta = 0.2$  (ie, a power of 0.8), this study should have detected a difference in means of 50% to 100%. A smaller difference in the means might be detected with a larger number of dogs, but such a difference would not be clinically important. Five dogs in each group is adequate to detect a large, clinically important difference. We conclude that a large difference between the two groups in recovery time for the three wavefronts does not exist.

We have placed emphasis on the initial postoperative appearance of phase 3, phase 2, and the migrating colonic complex as a marker of ileus resolution. We have assumed that the reappearance of these wavefronts denotes the com-



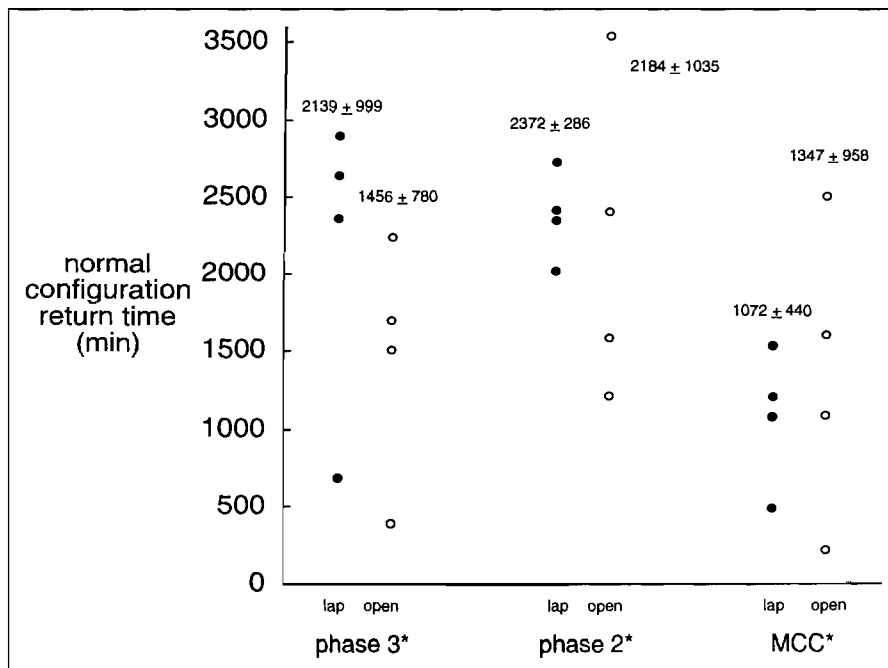
**Figure 2.** Comparison of preoperative (open bars) and postoperative (shaded bars) myoelectric parameters. A preoperative (before colectomy) bar represents data from >100 preoperative waveforms. A postoperative bar was calculated from the first three to five postoperative waveforms in each dog; therefore, each postoperative bar represents 20 to 25 waveforms. Error bars represent standard deviations. See text for definition of duration, migration velocity, and cycle length. \* $P < 0.05$ , unpaired  $t$  test, preoperative versus postoperative; open = open right hemicolectomy; lap = laparoscopically assisted right hemicolectomy; MCC = migrating colonic complex.

mencement of normal intestinal activity. However, by visually comparing the pre- and postoperative myoelectric record (not shown), it is apparent that the initial postoperative wavefronts do not have a normal (preoperative) configuration. This impression can be confirmed with a comparison of preoperative myoelectric parameters and the initial postoperative myoelectric parameters (Figure 2). The initial (first three to five) postoperative wavefronts are different from the preoperative wavefronts. Therefore, it is probably not correct to state that ileus is resolved at first sight of a migrating wavefront. Possibly a more accurate way to identify myoelectric resolution of ileus in this model is to determine when phase 2, phase 3, and the migrating colonic complex attain a normal (preoperative) configuration. Resolution of ileus after open versus laparoscopically assisted colectomy based on recovery of normally configured wavefronts is compared in Figure 3.

Our interpretation of this data is that there is no clinically important difference in the duration of postoperative ileus

in the dog after open versus laparoscopically assisted right hemicolectomy. This conclusion rests on the assumption, which has been supported,<sup>3</sup> that serosal myoelectric recording can describe peristalsis. Clinical indicators also may be used to describe peristalsis. We have been hesitant in dogs to apply indicators such as flatus, bowel movement, and tolerance of food because 24 hours of observation are required and a dog will often wait until it has the privacy of its own cage (away from the laboratory) to eat or have a bowel movement. The best assay of intestinal peristalsis is controversial; more methodology research is needed.

Our conclusion of no difference is not consistent with the clinical impression that the patient undergoing a laparoscopically assisted colectomy has a quicker resolution of ileus compared to the patient undergoing the equivalent open operation. This inconsistency may be because the dog has a quicker resolution of postoperative ileus compared to humans.<sup>4</sup> Alternatively, the inconsistency may be attributable to parenteral opioid analgesics, which have been shown to dis-



**Figure 3.** Time at which phase 3, phase 2, and the migrating colonic complex attained a normal configuration after open ( $n = 5$ ) versus laparoscopically assisted ( $n = 5$ ) right hemicolectomy in the dog. Normal configuration = wavefront duration, migration velocity, and cycle length for two consecutive cycles within 1 standard deviation of preoperative value. The value above each column of data is the mean  $\pm$  standard deviation. \* $P > 0.05$ , Wilcoxon rank sum test; open = open right hemicolectomy; lap = laparoscopically assisted right hemicolectomy; MCC = migrating colonic complex.

rupt colonic motility,<sup>5</sup> are used commonly after open operation in humans but were not used in this study. Perhaps it is the relative nonuse of opioid in the laparoscopic patient that accounts for the perceived rapid intestinal recovery. Psychological conditioning of the patient (eg, telling the laparoscopic patient preoperatively that postoperative recovery will be rapid) may shorten the duration of postoperative ileus,<sup>6</sup> and this also may explain the incongruency of our study with the clinical situation.

In some studies of canine postoperative ileus after open versus laparoscopic colectomy,<sup>7</sup> and cholecystectomy,<sup>8</sup> it was found that recovery of baseline myoelectric activity was quicker after laparoscopic operation. Similar studies of laparoscopic versus open cholecystectomy in the dog<sup>2</sup> and colectomy in the human,<sup>9</sup> and dog<sup>10</sup> found no difference. Solid phase gastric emptying and radiopaque marker transit, however, was quicker after laparoscopic operation.<sup>9,10</sup> Upon review of these data, one might conclude that some laparoscopic operations might have a shorter duration of ileus compared to the open operations, but it is doubtful that this difference would be large enough to be clinically important. We believe that the effect on bowel function of a laparoscopically assisted colon resection probably is equivalent to the effect of an open resection, and consequently surgeons often may be sending their laparoscopic patients home before ileus resolution.

The impression that postoperative ileus is shorter after laparoscopically assisted colectomy compared to open colectomy has not been confirmed by this study. Our inability to confirm the clinical impression may be due to differing conditions between our model and the clinical situation. Similar studies in the future may be more revealing if done in humans. We and others encourage the application of the

scientific method to problems such as postoperative ileus, which have been magnified by the rapid evolution of laparoscopic surgery.

## REFERENCES

- Ortega AE, Beart RW Jr, Steele GD Jr, et al. Laparoscopic bowel surgery registry: Preliminary results. *Dis Colon Rectum*. 1995;38:681-686.
- Ludwig KA, Frantzides CT, Carlson MA, Grade KL. Myoelectric motility patterns following open versus laparoscopic cholecystectomy. *J Laparoendosc Surg*. 1993;3:461-465.
- Waldenhausen JT, Shaffrey ME, Skenderis BS II, et al. Gastrointestinal myoelectric and clinical patterns of recovery after laparotomy. *Ann Surg*. 1990;211:777-785.
- Condon RE, Cowles VE, Ferraz AAB, et al. Human colonic smooth muscle electrical activity during and after recovery from postoperative ileus. *Am J Physiol*. 1995;269 (Gastrointest Liver Physiol 32):G408-G417.
- Frantzides CT, Cowles V, Salaymeh B, et al. Morphine effects on human colonic myoelectric activity in the postoperative period. *Am J Surg*. 1992;163:144-149.
- Drisbrow EA, Bennett HL, Owings JT. Effect of preoperative suggestion on postoperative gastrointestinal motility. *West J Med*. 1993;158:488-492.
- Bohm B, Milsom JW, Fazio VW. Postoperative intestinal motility following conventional and laparoscopic intestinal surgery. *Arch Surg*. 1995;130:415-419.
- Schippers E, Ottinger A, Anurov M, et al. Laparoscopic cholecystectomy: A minor abdominal trauma? *World J Surg*. 1993;17:539-543.
- Hotokezaka M, Combs MJ, Schirmer BD. Recovery of gastrointestinal motility is more rapid after laparoscopic versus open colon surgery (abstract). *Gastroenterology*. 1995;108(suppl):A617.
- Hotokezaka M, Combs MJ, Schirmer BD. Recovery of gastrointestinal motility following open versus laparoscopic colon resection in dogs. *Dig Dis Sci*. 1996;41:705-710.